Tidsskriftet Tidsskrift for Den norske legeforening

Gastric mucosa in the rectum

IMAGES IN MEDICINE

JØRGEN VALEUR

jorgen.valeur@lds.no
Unger-Vetlesen Institute
Lovisenberg Diakonale Hospital
and
Institute of Clinical Medicine
University of Oslo
Jørgen Valeur, specialist in internal medicine and gastroenterology, senior consultant and professor
The author has completed the ICMJE form and declares no conflicts of interest.

CAMILLA SPERSRUD HAUG

Department of Pathology
Division of Laboratory Medicine
Oslo University Hospital
Camilla Spersrud Haug, specialist in pathology and senior consultant
The author has completed the ICMJE form and declares no conflicts of interest.

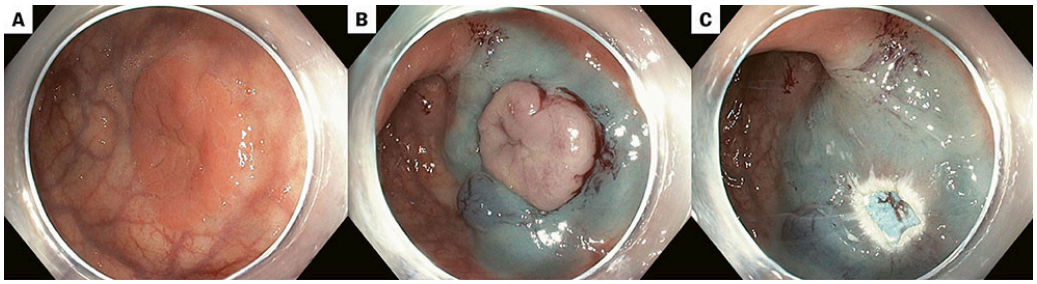

The endoscopic image (a) shows a 20 mm circular mucosal lesion in the rectum, 15 cm above the anal verge. The lesion was initially interpreted as a polyp and was removed via endoscopic mucosal resection, a technique in which dyed lifting solution is injected into the submucosa to elevate the lesion (b), followed by resection with a diathermic snare (c). The histologic image (d)

revealed that the specimen was not a polyp but consisted of gastric mucosa of corpus type (right side of the section), surrounded by normal colonic mucosa (left side of the section).

The patient was a previously healthy woman in her twenties who had been referred for gastroenterological evaluation due to recurrent rectal bleeding. Ileocolonoscopy was unremarkable except for the lesion in the rectum. Her symptoms resolved following removal of the lesion.

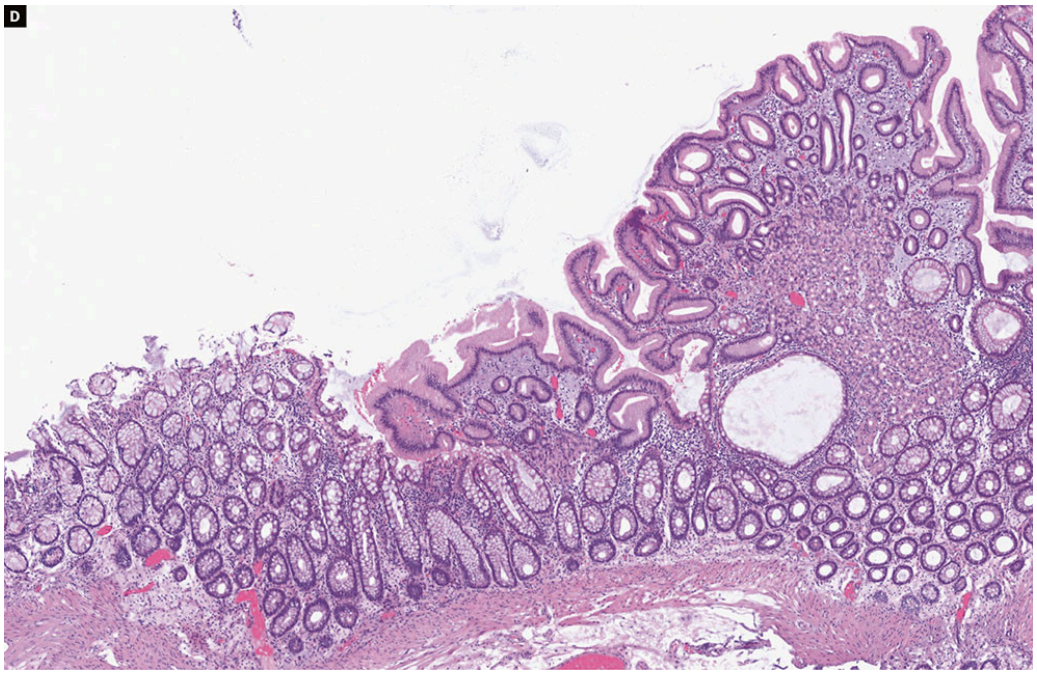

Ectopic gastric mucosa, also known as gastric heterotopia, refers to morphologically normal gastric mucosa located outside the stomach. The condition is believed to be congenital and can occur throughout the gastrointestinal tract, including within a Meckel's diverticulum, but is most frequently observed in the proximal oesophagus (and therefore often referred to as an inlet patch) (1). Gastric heterotopia of the rectum is extremely rare but, unlike oesophageal lesions, is often symptomatic (2). Because ectopic gastric mucosa secretes gastric acid, it can cause ulceration and may result in bleeding, perforation or stricture formation. Thus, peptic ulcer disease is not necessarily confined to the upper gastrointestinal tract.

The patient has consented to publication of the article.

The article has been peer-reviewed.

REFERENCES

1. Yu L, Yang Y, Cui L et al. Heterotopic gastric mucosa of the gastrointestinal tract: prevalence, histological features, and clinical characteristics. Scand J Gastroenterol 2014; 49: 138–44. [PubMed][CrossRef]

2. Devereaux CE, Devereaux RG. Heterotopic gastric mucosa of the rectum with a review of the literature. J Clin Gastroenterol 1994; 19: 41–5. [PubMed][CrossRef]

Publisert: 29. October 2025. Tidsskr Nor Legeforen. DOI: 10.4045/tidsskr.25.0492
Received 15.8.2025, accepted 29.9.2025.
Copyright: © Tidsskriftet 2026 Downloaded from tidsskriftet.no 5 July 2026.