
Liver cyst rupture after a fall

IMAGES IN MEDICINE

SANDRA STADHEIM

sastad@vestreviken.no

Surgical Department

Ringerike Hospital

Sandra Stadheim, specialty registrar in general surgery

The author has completed the ICMJE form and declares no conflicts of interest.

THOMAS JOHAN FYHN

Surgical Department

Ringerike Hospital

Thomas Johan Fyhn PhD, specialty registrar in general surgery

The author has completed the ICMJE form and declares no conflicts of interest.

JOHN CHRISTIAN GLENT

Surgical Department

Ringerike Hospital

John Christian Glent, specialist in general surgery and gastrointestinal surgery,
senior consultant

The author has completed the ICMJE form and declares the following conflicts
of interest: he has served as President of the Norwegian Society of Surgeons
and the Scandinavian Surgical Society.

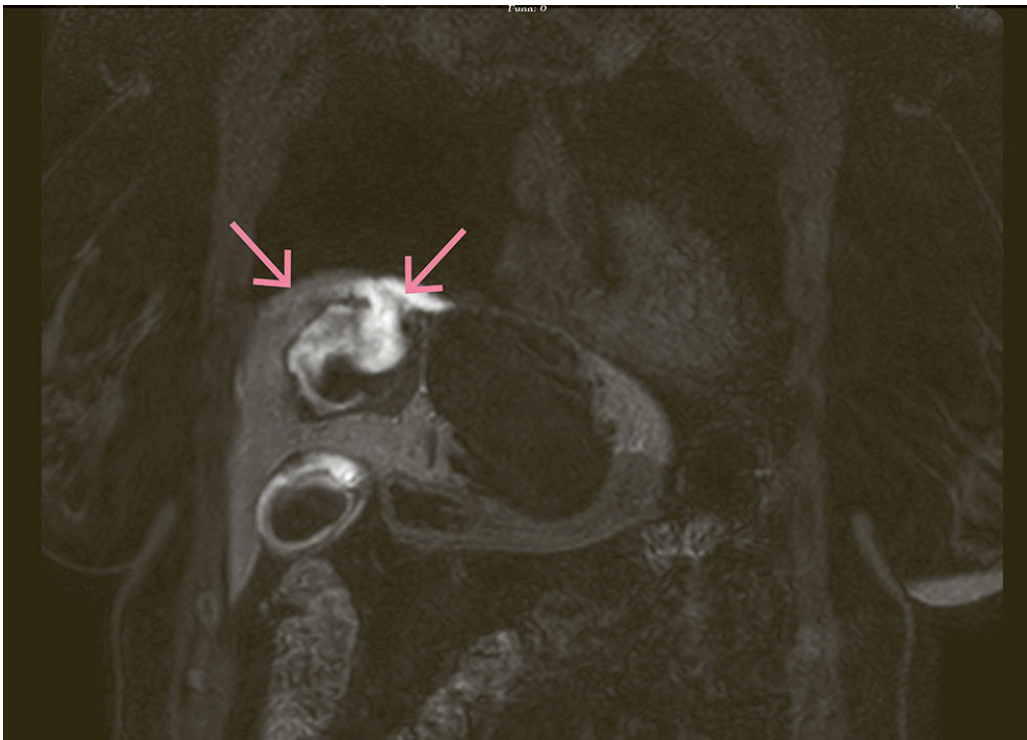
ADAM JACHIMOWICZ

Department of Radiology

Ringerike Hospital

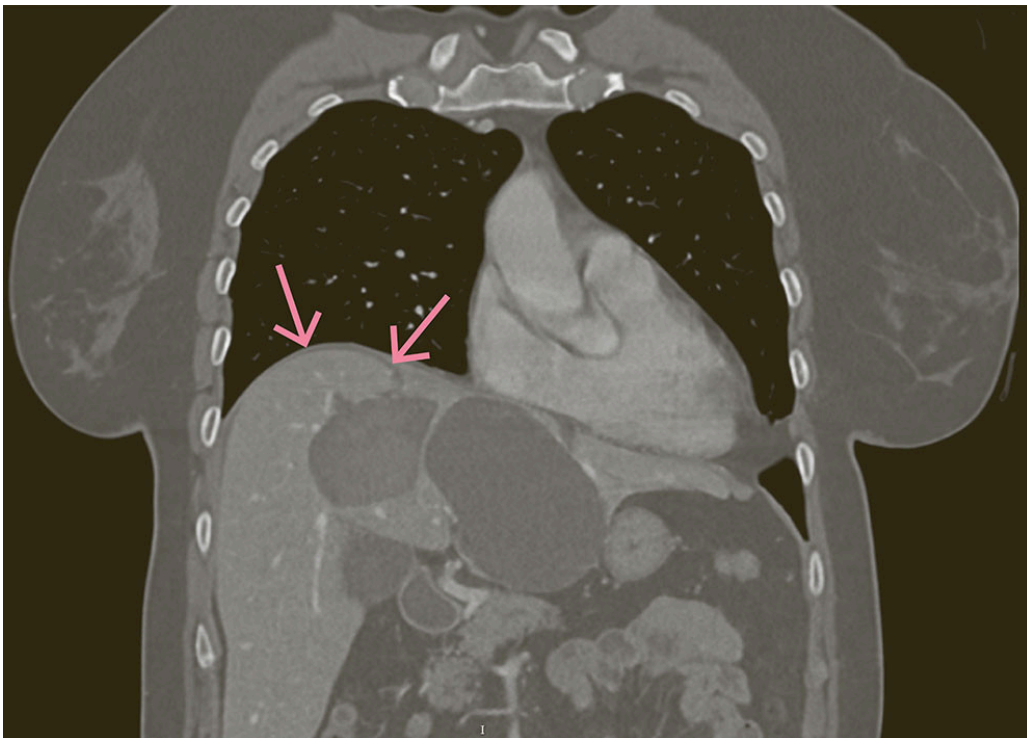
Adam Jachimowicz, specialist in radiology and senior consultant

The author has completed the ICMJE form and declares no conflicts of interest.



This MRI image was taken in the coronal plane, T1 Dixon water, hepatobiliary phase, 20 minutes after injection of gadoxetate disodium (Primovist) 1 ml/10 kg, to investigate post-traumatic bile leakage in a woman in her fifties diagnosed with fibropolycystic liver disease. The cyst in the image shows an inhomogeneous signal consistent with contrast and blood. Contrast can be seen extravasating from a ruptured cyst through a 14 mm opening into the perihepatic space, with associated bile leakage into the peritoneum (as indicated by the arrows).

The patient was assessed by the trauma team after a bicycle accident in which the handlebars struck her mid-abdomen. On admission she was stable but had diffuse abdominal tenderness on palpation. Trauma CT showed probable liver cyst rupture.



The following day, the patient underwent laparoscopy due to increasing peritonitis. Blood was found in the hepatorenal fossa and pelvis, as well as a liver cyst with fresh adhesions to the abdominal wall. The small intestine showed no signs of injury. A Blake drain was placed in the hepatorenal fossa (drain 1) and pelvis (drain 2). On the first postoperative day, 50 mL had drained from drain 1, appearing as diluted bile. The drain fluid measured bilirubin 330 µmol/L, and the amylase level was normal. The patient's pain continued to increase, and MRI of the liver with gadoxetate disodium was therefore performed to rule out leakage from other, non-visualised injuries. The MRI examination with hepatocyte-specific contrast showed bile leakage from the cyst in segment 4A and along drain 1. The clinical picture was thus consistent with well-drained biliary peritonitis. Drain output gradually decreased, and the drain was removed on postoperative day 16.

The prevalence of liver cysts is 1–18 % (1). Traumatic liver cyst rupture is a rare but relevant differential diagnosis in acute abdomen. In very rare cases, such as in our patient, biliary peritonitis may occur if the cyst communicates with the intrahepatic bile ducts (2). Biliary peritonitis following a cyst rupture can be a life-threatening condition, and the risk of rupture increases with the size of the cyst. Surgical lavage and drainage are the primary treatment. The prognosis is generally good, but some fatal cases have been reported. This does not justify recommending preventive volume-reducing treatment in patients diagnosed with a liver cyst (3).

The patient has consented to publication of the article.

The article has been peer-reviewed.

REFERENCES

1. Rawla P, Sunkara T, Muralidharan P et al. An updated review of cystic hepatic lesions. *Clin Exp Hepatol* 2019; 5: 22–9. [PubMed][CrossRef]
2. Matsuo H, Katayama K, Hayasaki A et al. Biliary peritonitis due to liver cyst rupture in autosomal dominant polycystic kidney disease. *BMC Gastroenterol* 2021; 21: 267. [PubMed][CrossRef]
3. European Association for the Study of the Liver. EASL Clinical Practice Guidelines on the management of cystic liver diseases. *J Hepatol* 2022; 77: 1083–108. [PubMed][CrossRef]

Publisert: 18. August 2025. Tidsskr Nor Legeforen. DOI: 10.4045/tidsskr.25.0120

Received 16.2.2025, first revision submitted 10.3.2025, accepted 11.6.2025.

Copyright: © Tidsskriftet 2026 Downloaded from tidsskriftet.no 10 July 2026.