
The routine prenatal ultrasound scan should be more comprehensive

OPINIONS

INE HILDERSHAVN MOEN

Ine Hildershavn Moen, midwife and head of section at the Department of Obstetrics and Gynaecology, Haukeland University Hospital, with postgraduate studies in ultrasound diagnostics and a master's degree in midwifery.

The author has completed the ICMJE form and declares no conflicts of interest.

SYNNØVE LIAN JOHNSEN

Synnøve Lian Johnsen, specialist in obstetrics and gynaecology, and head of the Section for Fetal Medicine and Ultrasound, Department of Obstetrics and Gynaecology, Haukeland University Hospital.

The author has completed the ICMJE form and declares no conflicts of interest.

HENRIETTE ODLAND KARLSEN

Henriette Odland Karlsen, PhD, specialist in obstetrics and gynaecology, and senior consultant at the Section for Fetal Medicine and Ultrasound, Department of Obstetrics and Gynaecology, Haukeland University Hospital.

The author has completed the ICMJE form and declares no conflicts of interest.

ANNE MARTHA STOKKE

Anne Martha Stokke, specialist in obstetrics and gynaecology, and senior consultant at the Department of Obstetrics and Gynaecology, Haukeland University Hospital.

The author has completed the ICMJE form and declares no conflicts of interest.

SVEIN RASMUSSEN

Svein Rasmussen, specialist in obstetrics and gynaecology, and professor emeritus at the University of Bergen.

The author has completed the ICMJE form and declares no conflicts of interest.

CATHRINE EBBING

cathrine.ebbing@helse-bergen.no

Cathrine Ebbing, specialist in obstetrics and gynaecology, senior consultant at the Section for Fetal Medicine and Ultrasound, Department of Obstetrics and Gynaecology, Haukeland University Hospital, and associate professor at the Department of Clinical Science, University of Bergen.

The author has completed the ICMJE form and declares no conflicts of interest.

A well-functioning placenta and umbilical cord are essential for a normal pregnancy. However, there is little focus on these organs in prenatal care.

Ultrasound examinations are important constituents of prenatal care and have strong popular support. In Norway, fetal ultrasound and Doppler examinations have helped to steadily reduce perinatal deaths despite the rising maternal age and morbidity rates among pregnant women (1, 2). All pregnant women are now offered an ultrasound during the first trimester in addition to the examination in week 18–19. Salvesen and Staff recently advocated for incorporating targeted screening for preeclampsia into the first-trimester examination (3). We believe that routine ultrasound examinations still have unrealised potential.

Examination of placenta and umbilical cord

Routine ultrasound examinations already include an assessment of the number of blood vessels in the umbilical cord and placental location. International recommendations stipulate that umbilical cord insertion should also be examined (4). The reason for performing an ultrasound examination of the placenta and umbilical cord is that it can identify variants associated with risk, such as when the placenta attaches low in the uterus (placenta previa) or where there is an abnormal number of blood vessels in the umbilical cord. In cases of velamentous cord insertion, the umbilical vessels are not protected by the umbilical cord or placenta and are therefore vulnerable to pressure and trauma.

High-risk pregnancy and fetal bleeding

Velamentous cord insertion is associated with a risk of adverse outcomes for both mother and child (5–8). In a small percentage of cases, the unprotected fetal blood vessels in the membranes lie across or near the internal os. This is known as vasa previa. When vasa previa is diagnosed, the goal is to deliver by caesarean section before spontaneous or induced rupture of the membranes. At term, a fetus has a blood volume of approximately 3–4 dL (110 ml/kg) and lacks adequate compensatory mechanisms if bleeding occurs. Within seconds, bleeding from a velamentous vessel can be fatal (9). Not surprisingly, the mortality rate for undiagnosed vasa previa is therefore high, up to 56 %, and if the child survives, there is a high risk of severe morbidity (10). However, if the condition is identified before birth, the survival rate is almost 100 %, with normal outcomes in the short and long term (11).

Velamentous vessels are more common in twin pregnancies, after assisted fertilisation and in older primiparous women. In Norway and most other countries, the prevalence of vasa previa at population level is unknown, but according to the literature, it occurs in between 1:365 and 1:5000 pregnancies (10). Interesting results were recently published from a study in which vasa previa was treated with fetoscopic ablation (12). This may enable women with vasa previa to have a normal delivery.

Diagnosing vasa previa

Although diagnosing vasa previa and velamentous vessels via ultrasound has been possible since the late 1980s, the routine examination in Norway does not include confirming or ruling out vasa previa. Transvaginal ultrasound has high sensitivity and specificity for diagnosing vasa previa (13), and false-positive and false-negative findings are rare. In addition, the examination is inexpensive, entails little patient discomfort, poses no risk to the fetus and is quick to perform (a few minutes) (Figure 1) (see the video at tidsskriftet.no).

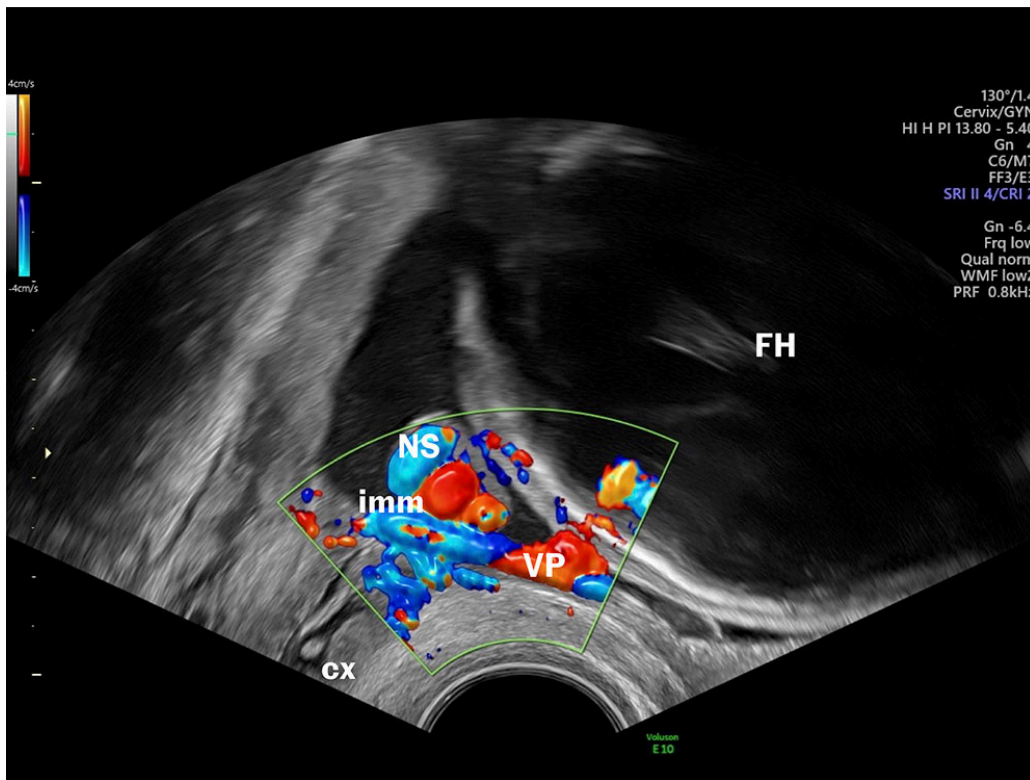


Figure 1 Vasa previa. Ultrasound image and video from a transvaginal ultrasound examination showing the cervix, lower edge of the placenta, fetal head, umbilical cord and blood vessels lying across the membranes, adjacent to the opening of the cervix. imm=internal cervical os, VP=vasa previa, NS=umbilical cord, cx=cervix, FH=fetal head

imm=internal cervical os, VP=vasa previa, NS=umbilical cord, cx=cervix, FH=fetal head

«Why is there no systematic screening for vasa previa, when this simple and effective examination can save lives and improve quality-adjusted life years?»

So why is there no systematic screening for vasa previa, when this simple and effective examination can save lives and improve quality-adjusted life years? There has been little focus on this topic in Norway, which may be due to resistance to medicalising pregnancy and excessive use of technology in prenatal care. Perhaps there is concern that the examination will lead to unnecessary caesarean sections and cause anxiety among patients, their family and healthcare personnel? Do midwives and obstetricians who perform ultrasounds lack confidence in carrying out transvaginal ultrasounds to confirm or rule out vasa previa?

The routine fetal ultrasound examination is a golden opportunity to further reduce risks during pregnancy. Since few fetal examinations have as great an impact on the outcome as diagnosing vasa previa, we believe it is time to systematically screen for this condition in prenatal care.

The patient has consented to publication of the image and video.

REFERENCES

1. Eskild A, Skau I, Haavaldsen C et al. Teknologi redder fosterliv. Tidsskr Nor Legeforen 2021; 141. doi: 10.4045/tidsskr.21.0256. [PubMed][CrossRef]
2. FHI. 40 prosent av kvinner som blir gravide i Norge er overvektige eller har fedme rett før svangerskapets start. <https://www.fhi.no/nyheter/2023/40-prosent-av-kvinner-som-blir-gravide-i-norge-er-overvektige-eller-har-fedme-rett-for-svangerskapets-start/> Accessed 18.1.2024.
3. Salvesen KAB, Staff AC. Ny og nyttig screening for preeklampsirisiko. Tidsskr Nor Legeforen 2023; 143. doi: 10.4045/tidsskr.22.0784. [PubMed][CrossRef]
4. Salomon LJ, Alfirevic Z, Berghella V et al. ISUOG Practice Guidelines (updated): performance of the routine mid-trimester fetal ultrasound scan. Ultrasound Obstet Gynecol 2022; 59: 840–56. [PubMed][CrossRef]
5. Ebbing C, Kiserud T, Johnsen SL et al. Prevalence, risk factors and outcomes of velamentous and marginal cord insertions: a population-based study of 634,741 pregnancies. PLoS One 2013; 8. doi: 10.1371/journal.pone.0070380. [PubMed][CrossRef]
6. Ebbing C, Rasmussen S, Kessler J et al. Association of placental and umbilical cord characteristics with cerebral palsy: national cohort study. Ultrasound Obstet Gynecol 2023; 61: 224–30. [PubMed][CrossRef]
7. Ebbing C, Kiserud T, Johnsen SL et al. Third stage of labor risks in velamentous and marginal cord insertion: a population-based study. Acta Obstet Gynecol Scand 2015; 94: 878–83. [PubMed][CrossRef]
8. Siargkas A, Tsakiridis I, Pachi C et al. Impact of velamentous cord insertion on perinatal outcomes: a systematic review and meta-analysis. Am J Obstet Gynecol MFM 2023; 5. doi: 10.1016/j.ajogmf.2022.100812. [PubMed][CrossRef]
9. Toubas PL, Silverman NH, Heymann MA et al. Cardiovascular effects of acute hemorrhage in fetal lambs. Am J Physiol 1981; 240: H45–8. [PubMed]
10. Oyelese Y, Javinani A, Shamshirsaz AA. Vasa Previa. Obstet Gynecol 2023; 142: 503–18. [PubMed][CrossRef]
11. Conyers S, Oyelese Y, Javinani A et al. Incidence and causes of perinatal death in prenatally diagnosed vasa previa: a systematic review and meta-analysis. Am J Obstet Gynecol 2024; 230: 58–65. [PubMed][CrossRef]

12. Chmait RH, Monson MA, Chon AH et al. Third-trimester fetoscopic ablation therapy for types II and III vasa previa. *Am J Obstet Gynecol* 2024; 230: 87.e1–9. [PubMed][CrossRef]
 13. Gross A, Markota Ajd B, Specht C et al. Systematic screening for vasa previa at the 20-week anomaly scan. *Acta Obstet Gynecol Scand* 2021; 100: 1694–9. [PubMed][CrossRef]
-

Publisert: 19. March 2024. Tidsskr Nor Legeforen. DOI: 10.4045/tidsskr.24.0042
Copyright: © Tidsskriftet 2026 Downloaded from tidsskriftet.no 4 July 2026.