
A woman in her sixties with epilepsy and syncope

EDUCATIONAL CASE REPORT

JANA MIDELFART-HOFF

jmid@helse-bergen.no
Department of Neurology
Haukeland University Hospital
and
VID Specialized University
Faculty of Health Studies
Bergen

Jana Midelfart-Hoff, senior consultant and neurologist.

The author has completed the ICMJE form and declares no conflicts of interest.

GREGORZ GRADEK

Heart and Lung Centre Bergen
Gregorz Gradek, specialist in internal medicine and cardiology, working in private practice.

The author has completed the ICMJE form and declares no conflicts of interest.

ØYSTEIN WENDELBO

Department of Heart Disease
Haukeland University Hospital
and
VID Specialized University
Faculty of Health Studies
Bergen

Øystein Wendelbo, senior consultant and specialist in infectious diseases.

The author has completed the ICMJE form and declares no conflicts of interest.

BERNT ANDREAS ENGELSEN

Department of Neurology
Haukeland University Hospital
and
University of Bergen

Bernt Andreas Engelsen, specialist in neurology and professor emeritus at the University of Bergen.

The author has completed the ICMJE form and declares no conflicts of interest.

BACKGROUND

A woman in her sixties had been diagnosed with generalised epilepsy twenty years earlier. The diagnosis was confirmed by EEG, and an MRI scan revealed hippocampal sclerosis, which is not uncommon in patients with epilepsy. Treatment with carbamazepine was initiated.

CASE PRESENTATION

Due to a rise in the patient's cholesterol, carbamazepine was replaced with oxcarbazepine. At a follow-up, the patient reported a recent episode with loss of consciousness. Unstable epilepsy was suspected and the oxcarbazepine dose increased. The patient had had a minor stroke shortly before the check-up. As part of the diagnostic workup, a 24-hour ECG was performed. On removal of the apparatus, the patient described an episode with loss of consciousness that same morning. The ECG showed asystole at that point in time due to total AV block. A pacemaker was implanted, and the patient has had no episodes since.

INTERPRETATION

The patient retrospectively reported recurrent episodes with loss of consciousness over many years. The diagnosis of epilepsy was convincing, but was the heart condition linked to her epilepsy, her medication or was it a separate entity? When seizures become more frequent or change character in a previously stabilised patient with epilepsy, it is important to look for non-epileptic causes, and cardiac arrhythmias should be high on the list.

At a routine neurology outpatient appointment, a woman in her sixties with a 30-year history of well-controlled epilepsy reported a recent seizure. The dose of her antiepileptic medication was therefore increased. However, the cause of the seizure turned out to be something else entirely.

A woman in her sixties had been admitted to the neurology department some 30 years prior to the episode in question, with what was described in her medical records as a very convincing seizure with clear epileptic changes on an electroencephalogram (EEG). Prior to the seizure, she had been in good health

with no known medical conditions. Treatment was initiated with the antiepileptic drug carbamazepine (Tegretol) in tablet form (300 mg × 3). A few years later, the patient underwent magnetic resonance imaging (MRI) to determine whether her epilepsy was caused by structural pathology. The MRI revealed pathological hyperintensity in the right hippocampal area, which was interpreted as hippocampal sclerosis.

The hippocampus is an area of the brain deep within each of the temporal lobes. Its name is derived from the Greek word for seahorse, *hippokampos*, on account of its shape, which is considered to resemble that of a small seahorse. The hippocampus has a key role in learning and short-term memory, and is present within the brains of all vertebrates. In adult humans, hippocampal sclerosis is associated with treatment-refractory epilepsy. As well as being a cause of epilepsy, hippocampal sclerosis can itself be caused by prolonged epileptic seizures. The hippocampus is also vulnerable to disease and injury, including traumatic brain injury and inflammatory disorders [\(1\)](#).

The patient received regular outpatient follow-up in the neurology department and remained in good health. However, an EEG performed five years after her first hospitalisation still showed changes consistent with epilepsy. She remained on carbamazepine for a further five years. In agreement with a neurologist, carbamazepine was then discontinued because the patient had been seizure-free for many years and was experiencing possible side effects, including fatigue and cognitive slowing. However, the following year, the patient returned to the neurology department after another seizure, and was therefore restarted on carbamazepine tablets (300 mg × 3). Sixteen years later, carbamazepine was switched to oxcarbamazepine (Trileptal) in tablet form (450 mg × 2) in an attempt to achieve a more favourable side effect profile, not least a better lipid profile, as she had been found to have high cholesterol.

Many patients with epilepsy require lifelong medication. Long-term use of carbamazepine has been shown to increase the risk of vascular disease (including cardiovascular disease), through mechanisms including more rapid development of atherosclerosis [\(2\)](#). Carbamazepine can also give rise to cardiac arrhythmias [\(3\)](#). Oxcarbamazepine is not associated with these side effects to the same extent [\(3\)](#), and was therefore considered a good alternative for this patient.

Two years after the change of medication, the patient attended a routine appointment at the neurology outpatient clinic. There she described an episode in which she had lost consciousness while standing at her kitchen counter making coffee. She was unsure how long she had been unconscious, but described it as though it were a few seconds. She regained consciousness on the floor, and discovered that she had spilt coffee on her trousers. She was suspected of having uncontrolled epilepsy, and after serum measurement revealed her oxcarbamazepine levels to be in the lower therapeutic range, her medication dose was increased to 500 mg × 2.

When a patient with stable epilepsy experiences a breakthrough seizure, it is important to look for possible precipitating factors. The first thing to consider is medication compliance. In a Norwegian study, over 20 % of the patients included occasionally forgot to take their medication, while 19 % were not

following their treatment plan (4). It is therefore important to ask patients directly about how they take their medication and whether they often miss doses. Measuring serum levels can be of great help, including as a pedagogical tool in conversations with the patient. Serum measurements in the current patient showed her to be within the therapeutic window for both medications.

The next consideration is whether other conditions might have changed. Intercurrent disease or changes in a known brain disease with epileptogenic properties (e.g. growth of a brain tumour) can exacerbate seizures. High levels of stress, lack of sleep, and menstruation are also established seizure triggers (5). Imaging should be performed if seizures have changed character or have become more frequent after a period of stability.

It may often be necessary to add a new medication to improve seizure control, or even to change the medication completely. In the first instance, however, one would usually choose to adjust the dose, as happened with the current patient.

At a routine neurology outpatient appointment a few months later, the patient reported having had another seizure. Again, this had happened first thing in the morning as she was making coffee. As she went to sit down in a chair, she suddenly felt as though the ground disappeared from beneath her, and she collapsed and fell to the floor. Her husband entered the room immediately and found her lying on the floor. He estimated that she was unconscious for around ten seconds. No seizures or urinary incontinence were observed, but she had snoring respiration.

Shortly before this episode, the patient's general practitioner had arranged for her to have a brain MRI on account of frequent headaches. This had revealed a fairly recent cerebral infarct in the left part of the cerebellum. The patient had therefore been referred to a private cardiologist to be assessed for underlying cardiac disease.

At the neurology clinic, the seizure was judged to be related to the patient's epilepsy and possibly also to her recent stroke. Her medication was left unchanged from the last appointment.

Studies have shown that the incidence of post-stroke epilepsy is initially 2.5 %, doubling over the course of five years (6, 7). The condition is more frequent in elderly patients, and is defined as two or more seizures more than four weeks after a stroke (7). The size of the infarct appears to be a risk factor (6, 7), which may explain why strokes in the anterior cerebral circulation appear more likely to trigger epilepsy than those in the posterior cerebral circulation, because the former encompasses a larger volume of the brain (8). Involvement of the temporal lobes also appears to increase the risk of post-stroke epilepsy (9).

The patient thus had two reasons to continue with her anti-seizure medication: her epilepsy and now also the stroke. The stroke had probably been 'silent'; it is very rare for the initial symptoms of a stroke to include epileptic or non-epileptic seizures. When a stroke has been confirmed, however, it is important to investigate possible causes and to begin suitable secondary prophylaxis to reduce the risk of another infarct.

In the autumn of that year, the patient was examined by a cardiologist in private practice. Electrocardiography (ECG) showed sinus rhythm 71 beats per minute, PQ interval <0.14 s (reference range 0.12–0.21), QRS duration 96

ms (<120) and an ST segment described as within the normal range (Figure 1). Echocardiography, including three-dimensional echocardiography, revealed a heart of normal size and location, normal movement of the heart valves and ventricular walls, and normal valvular flow velocities.

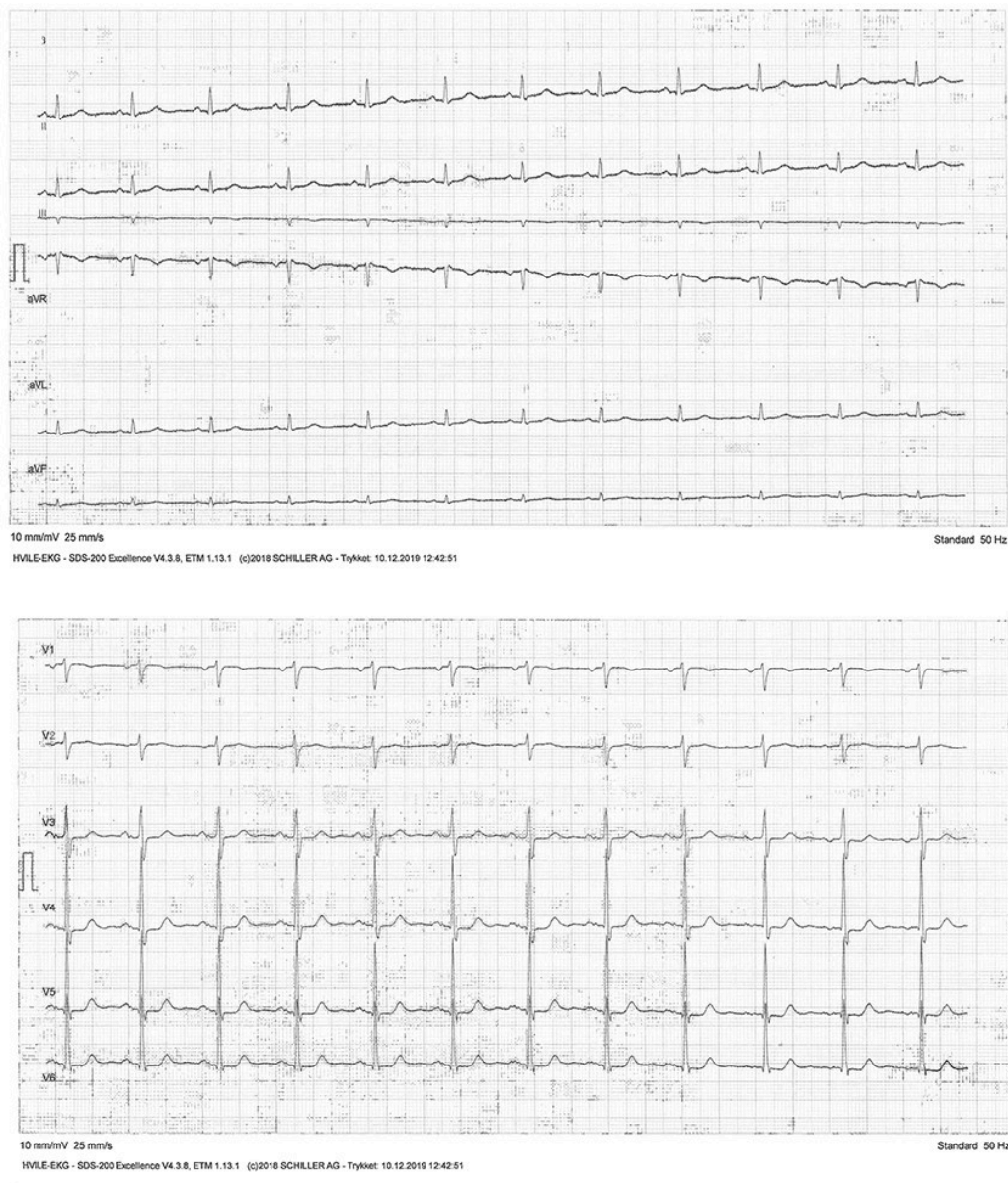


Figure 1 Resting ECG showing sinus rhythm and a normal electrical axis in all 12 leads.

When the patient returned the following day after 24-hour ECG recording (Holter monitoring), her husband reported that she had suddenly collapsed for a few seconds during breakfast that morning. She had lost consciousness, but once again there was no sign of convulsions, tongue biting or urinary incontinence.

The cardiologist reviewed the recording and found sinus rhythm throughout the previous 24 hours. However, at the time of the incident that morning, a few seconds of 2:1 AV block could be seen prior to complete heart block with no junctional escape rhythm, and asystole lasting 30 seconds. This was followed by three heartbeats with normal QRS complexes (Figure 2). The cardiologist considered the condition to be probable first-degree AV block with prolongation of the PQ interval. The recording showed no other arrhythmia and no significant ventricular or supraventricular extrasystoles.

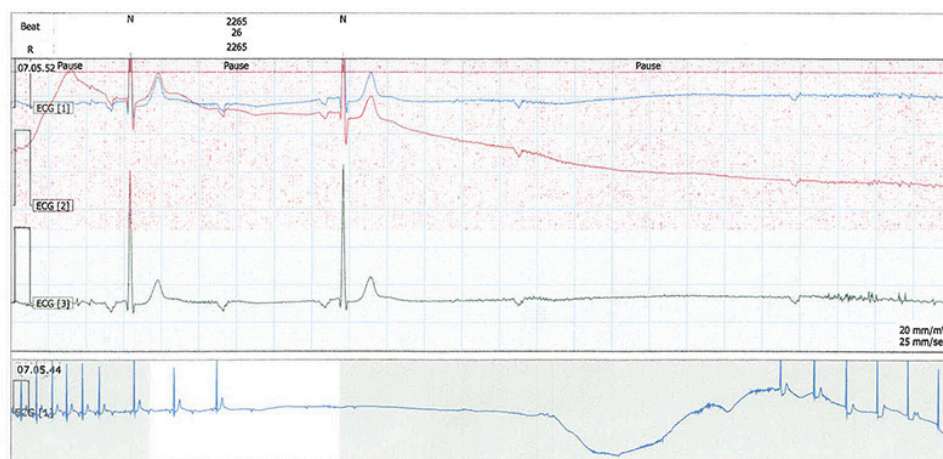


Figure 2 24-hour ECG from the time the patient lost consciousness shows a loss of QRS complexes, followed by complete AV block with no junctional escape rhythm and asystole lasting 30 seconds, likely reflecting first-degree AV block with prolongation of the PQ interval.

The patient was admitted to the cardiology department that same day, and was found to require implantation of a permanent pacemaker. Following the procedure, the patient was discharged in good general condition.

When the pacemaker was checked six months later, the patient was in good health and had had no further episodes with loss of consciousness. An ECG was normal, showing sinus rhythm and a fully functional pacemaker. When asked directly, the patient reported that for many years she had been experiencing episodes of syncope/near syncope in the mornings. She continued to take oxcarbamazepine, now reduced to her previous dose of 450 mg × 2.

Discussion

Patients who suddenly begin to experience transient loss of consciousness are often referred to neurologists to be assessed for epilepsy. Individuals with recurrent syncope tend to be regular attendees at neurology outpatient clinics, often after having been evaluated for other conditions, although not always. One important differential diagnosis is cardiac syncope. The main cause of cardiac syncope is arrhythmia, but it can also result from structural heart disease or cardiopulmonary disease (10). The cause of the loss of consciousness can often be determined by taking a thorough medical history, backed up by information from those who know the patient. This highlights the importance of a good anamnesis in providing a basis for further diagnostic testing. Syncope occurring during exertion or while standing, with acute onset and rapid spontaneous recovery, is often cardiac in nature, especially if the anamnesis reveals a family history of sudden cardiac death or known heart disease (10).

However, it is not always easy to distinguish epileptic seizures from cardiac syncope. While it used to be thought that cardiac syncope mainly occurred during physical activity, studies now suggest that it may also occur as a sudden unexpected loss of consciousness with no obvious trigger or as convulsive seizures during sleep (11). Establishing the cause of syncope and determining the appropriate treatment can therefore be challenging, and requires interdisciplinary collaboration. This is reflected by the European Society of Cardiology 2018 guidelines for the diagnosis and treatment of syncope, which were prepared on the basis of input from specialists in internal medicine, emergency medicine and neurology in addition to cardiologists (10). The guidelines emphasise that patients should ideally undergo assessment and risk stratification in a broader professional context, preferably by a dedicated interdisciplinary syncope team. This already happens to some degree in Norwegian emergency departments, where a triage doctor will assess large numbers of patients and call upon other specialists if needed. However, achieving this in an outpatient setting is often more complicated.

In patients with known epilepsy, it may be reasonable to assume that events that would otherwise be regarded as syncope can instead be attributed to their epilepsy. Symptoms and signs that suggest an epileptic aetiology include tongue biting, abnormal behaviours, postictal confusion and preictal discomfort (prodromal déjà vu or jamais vu) (12).

Patients with chronic epilepsy have high levels of comorbidity, including autoimmune diseases, heart disease and psychiatric disorders. They also have an increased risk of premature mortality, often ascribed to *sudden unexpected death in epilepsy* (SUDEP) (13, 14), defined as 'sudden, unexpected, non-traumatic, non-drowning death in an individual with epilepsy, witnessed or unwitnessed, in which autopsy does not reveal an anatomical or toxicological cause of death' (15). Risk factors associated with this form of sudden, unexpected death include frequent generalised seizures, younger age, poor compliance with antiepileptic drug treatment, and poor seizure control in general (16, 17). Another feared and potentially fatal condition in patients with epilepsy is status epilepticus, defined as a seizure that lasts more than 30 minutes or more than 30 minutes of multiple seizures with no recovery of consciousness in between (18).

It is important for doctors to be aware of SUDEP and status epilepticus as causes of seizure-related deaths, but studies suggest that they account for only a small proportion of all deaths of patients with epilepsy (13, 14). The main causes of premature death are somatic conditions such as cancer and cardiovascular/cerebrovascular disease, and studies suggest that this is often forgotten (19, 20).

Studies in patients with chronic epilepsy have shown disturbances in heart rate and rhythm and in cardiac repolarisation not only *during* seizures, but also interictally (21). These may result from ion channel dysfunction, caused either by the epilepsy itself or by inherited genetic variants that give rise both to epilepsy and to arrhythmia (21).

In our view, the origin of the current patient's illness was her epilepsy, diagnosed on the basis of convincing EEG findings and related to observed hippocampal sclerosis. She then developed cardiac arrhythmia, and it is possible that her many years of antiepileptic drug use (carbamazepine) may have contributed to this. In addition, hippocampal sclerosis per se can increase the risk of autonomic cardiovascular dysfunction [\(22\)](#).

When a patient whose epilepsy has been well-controlled for many years suddenly begins to have recurrent seizures, one should be alert to the possibility that something other than the epilepsy may be causing them. In hindsight, this should probably have been considered for our patient during her second follow-up after the change in medication. However, in a busy outpatient setting, this may have been overlooked due to the fact that the patient had recently had a stroke, which in itself increases the risk of subsequent epilepsy. In addition, the patient was being called in for more frequent follow-up than normal in recognition of the fact that her condition was unstable.

Nevertheless, it is important to emphasise that when patients with previously stable epilepsy experience persistent deterioration and increased seizure frequency, there should be a low threshold for considering alternative aetiology. Given that not only epilepsy, but also treatment with antiepileptic drugs can trigger cardiac arrhythmia, this should be high on the list of differential diagnoses, with a correspondingly low threshold for referring patients for cardiac assessment.

The patient has consented to the publication of this article.

The article has been peer-reviewed.

LITERATURE

1. Walker MC. Hippocampal sclerosis: Causes and prevention. *Semin Neurol* 2015; 35: 193–200. [[PubMed](#)][[CrossRef](#)]
2. Chuang YC, Chuang HY, Lin TK et al. Effects of long-term antiepileptic drug monotherapy on vascular risk factors and atherosclerosis. *Epilepsia* 2012; 53: 120–8. [[PubMed](#)][[CrossRef](#)]
3. Svendsen T, Alfstad KÅ, Lossius MI et al. Langtidsbivirkninger av antiepileptika. *Tidsskr Nor Lægeforen* 2016; 136: 324–7. [[PubMed](#)][[CrossRef](#)]
4. Henning O, Lossius MI, Lima M et al. Refractory epilepsy and nonadherence to drug treatment. *Epilepsia Open* 2019; 4: 618–23. [[PubMed](#)][[CrossRef](#)]
5. Nakken KO, Refsland G, Lillestølen KM et al. Anfallsutløsende faktorer ved epilepsi–hva mener pasientene? *Tidsskr Nor Lægeforen* 2005; 125: 2172–4. [[PubMed](#)]
6. Lossius MI, Rønning OM, Mowinckel P et al. Incidence and predictors for post-stroke epilepsy. A prospective controlled trial. The Akershus stroke study. *Eur J Neurol* 2002; 9: 365–8. [[PubMed](#)][[CrossRef](#)]

7. Lossius MI, Rønning OM, Gjerstad L. Epilepsi etter hjerneslag. *Tidsskr Nor Lægeforen* 2004; 124: 620–2. [PubMed]
8. Pande SD, Lwin MT, Kyaw KM et al. Post-stroke seizure-Do the locations, types and managements of stroke matter? *Epilepsia Open* 2018; 3: 392–8. [PubMed][CrossRef]
9. Keller L, Hobohm C, Zeynalova S et al. Does treatment with t-PA increase the risk of developing epilepsy after stroke? *J Neurol* 2015; 262: 2364–72. [PubMed][CrossRef]
10. Brignole M, Moya A, de Lange FJ et al. 2018 ESC Guidelines for the diagnosis and management of syncope. *Eur Heart J* 2018; 39: 1883–948. [PubMed][CrossRef]
11. Moya A, Sutton R, Ammirati F et al. Guidelines for the diagnosis and management of syncope (version 2009). *Eur Heart J* 2009; 30: 2631–71. [PubMed][CrossRef]
12. Sheldon R, Rose S, Ritchie D et al. Historical criteria that distinguish syncope from seizures. *J Am Coll Cardiol* 2002; 40: 142–8. [PubMed][CrossRef]
13. Nakken KO. Epilepsi – mer enn anfall. *Tidsskr Nor Legeforen* 2019; 139. doi: 10.4045/tidsskr.19.0149. [PubMed][CrossRef]
14. Gaitatzis A, Carroll K, Majeed A et al. The epidemiology of the comorbidity of epilepsy in the general population. *Epilepsia* 2004; 45: 1613–22. [PubMed][CrossRef]
15. Shankar R, Donner EJ, McLean B et al. Sudden unexpected death in epilepsy (SUDEP): what every neurologist should know. *Epileptic Disord* 2017; 19: 1–9. [PubMed][CrossRef]
16. Verducci C, Hussain F, Donner E et al. SUDEP in the North American SUDEP Registry: The full spectrum of epilepsies. *Neurology* 2019; 93: e227–36. [PubMed][CrossRef]
17. Sveinsson O, Andersson T, Mattsson P et al. Clinical risk factors in SUDEP: A nationwide population-based case-control study. *Neurology* 2020; 94: e419–29. [PubMed][CrossRef]
18. Cloyd J, Hauser W, Towne A et al. Epidemiological and medical aspects of epilepsy in the elderly. *Epilepsy Res* 2006; 68 (Suppl 1): 39–48. [PubMed][CrossRef]
19. Keezer MR, Bell GS, Neligan A et al. Cause of death and predictors of mortality in a community-based cohort of people with epilepsy. *Neurology* 2016; 86: 704–12. [PubMed][CrossRef]
20. Smith PE. Epilepsy: mimics, borderland and chameleons. *Pract Neurol* 2012; 12: 299–307. [PubMed][CrossRef]

21. Li MCH, O'Brien TJ, Todaro M et al. Acquired cardiac channelopathies in epilepsy: Evidence, mechanisms, and clinical significance. *Epilepsia* 2019; 60: 1753–67. [PubMed][CrossRef]
 22. Koseoglu E, Kucuk S, Arman F et al. Factors that affect interictal cardiovascular autonomic dysfunction in temporal lobe epilepsy: role of hippocampal sclerosis. *Epilepsy Behav* 2009; 16: 617–21. [PubMed][CrossRef]
-

Publisert: 26. January 2022. Tidsskr Nor Legeforen. DOI: 10.4045/tidsskr.21.0152

Received 27.6.2021, accepted 28.9.2021.

Published under open access CC BY-ND. Downloaded from tidsskriftet.no 3 July 2026.