

Brown serum

IMAGES IN MEDICINE

HELLE BORGSTRØM HAGER

helle.hager@siv.no

Central Laboratory

Vestfold Hospital Trust

Helle Borgstrøm Hager, specialist in medical biochemistry and head senior consultant.

The author has completed the ICMJE form and declares no conflicts of interest.

MAGNUS MOKSNES

Haematology Unit

Department of Medicine

Vestfold Hospital Trust

Magnus Moksnes, senior consultant

The author has completed the ICMJE form and declares no conflicts of interest.

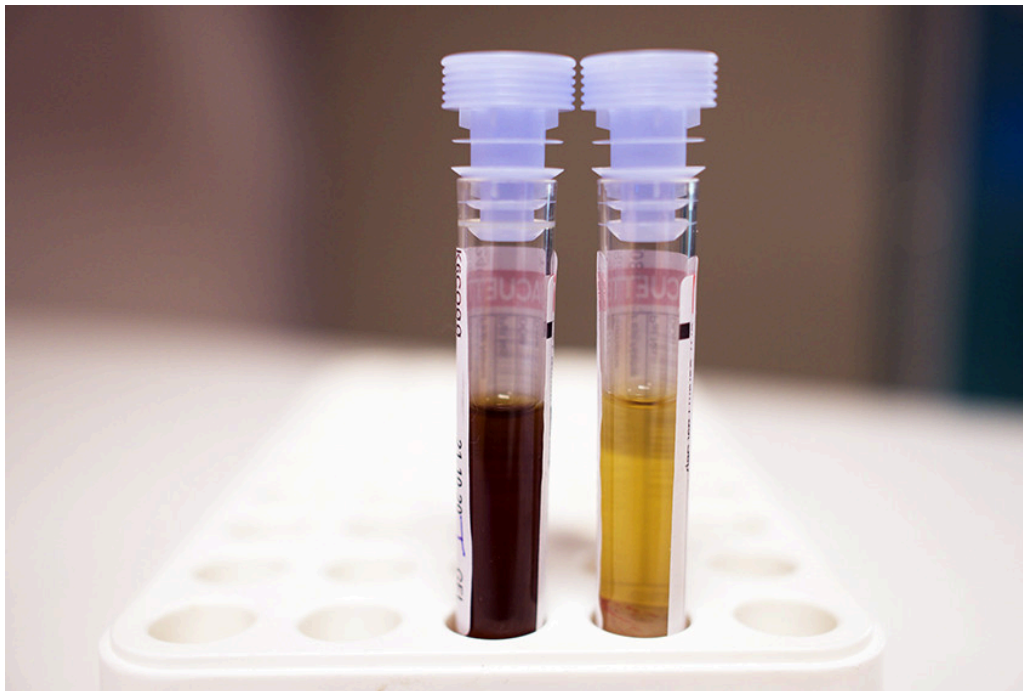
METTE BROKNER

Central Laboratory

Vestfold Hospital Trust

Mette Brokner, specialist in medical biochemistry and senior consultant.

The author has completed the ICMJE form and declares no conflicts of interest.



The picture shows tubes with brown and normal-coloured serum. The brown sample was taken from a man in his thirties who was admitted with infection and graft failure after an allogeneic haematopoietic stem cell transplantation for acute myelogenous leukaemia.

Brown-coloured serum is normally caused by serious conditions such as massive intravascular haemolysis or methemoglobinaemia. In intravascular haemolysis, haemoglobin from the erythrocytes will be released and bind to haptoglobin in the circulation. Haemoglobin-haptoglobin complexes are formed, but rapidly eliminated by monocytes and macrophages, and the haptoglobin concentration falls to non-measurable levels. In more comprehensive haemolysis, the binding capacity of haptoglobin will be exceeded. The iron contained in haemoglobin oxidises, and methaemoglobin is formed. Metheme is released and binds to albumin (methemealbumin) and haemopexin for transport to the liver where it will be broken down into bilirubin. Methemalbumin and haemopexin lend a coffee-brown colour to serum.

Methemoglobinaemia can also be caused by oxidising drugs (such as dapsone and certain antimalarials) or toxins, and in rare cases may be congenital. Blood that contains more than 10–15 % methemoglobin takes on a chocolate brown colour [\(1\)](#).

In the patient, methemoglobin was measured at 5 % (reference range < 2), while the haptoglobin level was 2.44 g/L (0.40–1.90) and bilirubin was 17 $\mu\text{mol/L}$ (< 25). The patient was using dapsone as prophylaxis against pneumocystis pneumonia. This could explain the slight methemoglobinaemia, but not the dark brown colour of the serum.

The patient's serum remained brown after discontinuation of dapsone. He was also undergoing treatment with eltrombopag (150 mg daily), a thrombopoietin receptor antagonist that can be administered for severe aplastic anaemia and immunological thrombocytopenia. The drug has a strong colour in itself and discolours serum in high dosages, and can also cause an icterus-like colour on

the skin and sclera (2). It is useful for clinicians and laboratory staff to be aware that high doses of eltrombopag can cause serum to turn brown. The brown colour can also cause analytical interference in certain spectrophotometric assays.

The patient has consented to publication of the article. The article has been peer reviewed.

LITERATURE

1. Solheim L, Brun AC, Greibrokk TS et al. Methemoglobinemia—causes, diagnosis and treatment. Tidsskr Nor Lægeforen 2000; 120: 1549–51. [PubMed]
 2. Rodgers GM, Kurtti AL, Gilreath JA. Are eltrombopag plasma and skin hyperpigmentation related? The eyes have it. Am J Hematol 2019; 94: 394–5. [PubMed][CrossRef]
-

Publisert: 25. October 2021. Tidsskr Nor Legeforen. DOI: 10.4045/tidsskr.21.0418

Received 18.5.2021, first revision submitted 17.8.2021, accepted 27.8.2021.

Copyright: © Tidsskriftet 2026 Downloaded from tidsskriftet.no 3 July 2026.