
Tongue-tie in neonates

PERSPECTIVES

ANE CHARLOTTE HAUG

Ane Charlotte Haug, specialty registrar at the University Hospital of North Norway, Harstad.

The author has completed the ICMJE form and declares no conflicts of interest.

TROND MARKESTAD

Trond Markestad, professor emeritus at the Department of Clinical Science, University of Bergen, and research advisor at the Department of Research, Innlandet Hospital Trust, Brumunddal.

The author has completed the ICMJE form and declares no conflicts of interest.

ERLING TJORA

Erling Tjora, senior consultant at the Department of Paediatric and Adolescent Medicine, Haukeland University Hospital, and postdoctoral research fellow at the Department of Clinical Science, University of Bergen.

The author has completed the ICMJE form and declares no conflicts of interest.

DAG MOSTER

dag.moster@uib.no

Dag Moster, senior consultant at the Department of Paediatric and Adolescent Medicine, Haukeland University Hospital, and professor at the Department of Global Public Health and Primary Care, University of Bergen.

The author has completed the ICMJE form and declares no conflicts of interest.

In recent years, an increasing proportion of neonates have had their tongue-tie cut owing to difficulties with breastfeeding. However, the evidence base in support of this intervention is weak. We are concerned that ever more neonates are being subjected to this procedure unnecessarily.

Ankyloglossia ('tongue-tie') in neonates has received increasing attention both in Norway and internationally because many believe it to be a key cause of difficulties with breastfeeding (1–3). However, both the diagnosis and the clinical significance of tongue-tie are controversial (4–9). This is illustrated by the fact that the reported prevalence in neonates varies from less than 1 % to 12 %, and by the fact that an increasing number of neonates have received the diagnosis in recent years (5–10). According to the Norwegian Patient Register, 2.8 % of neonates in Norway were diagnosed with tongue-tie in 2019, and 2.2 % underwent surgery on the tongue-tie within four weeks of birth (Figure 1). This year, seven times as many diagnoses were made and 13 times as many surgical procedures performed as in 2008 (Figure 1). Similar developments are also occurring in other countries (6, 7). However, there is little consensus on the basis for the diagnosis, the associated symptoms, or the indication for treatment (3–5), (5, 11, 12). Based on a review of the literature and our own clinical experience, we believe a more cautious approach to surgical intervention is warranted than the trend we see today.

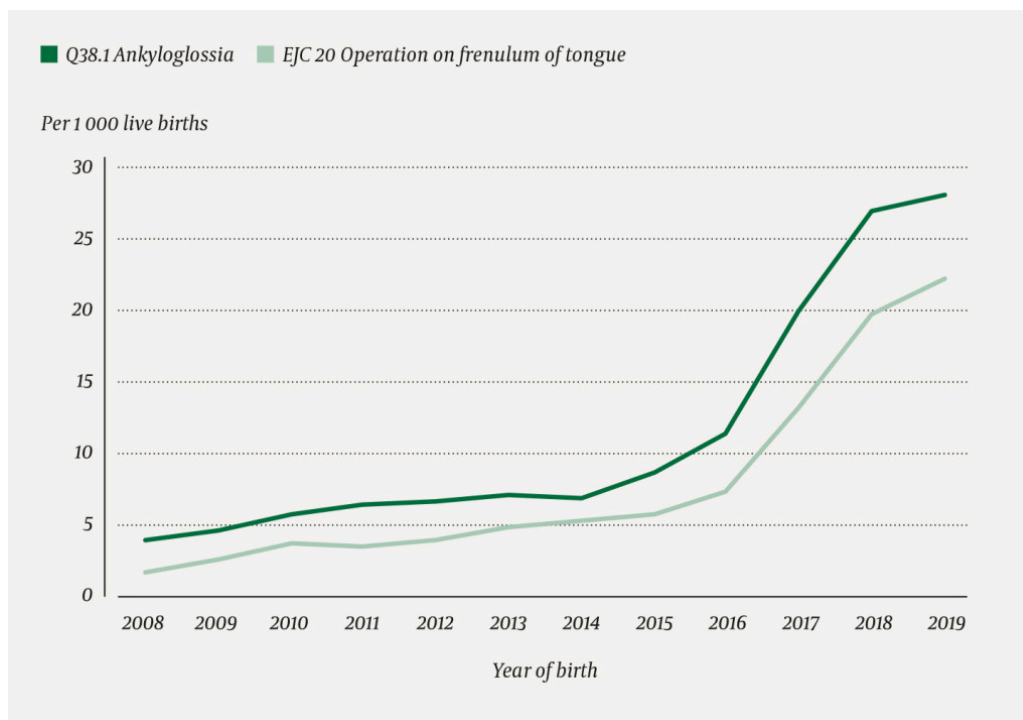


Figure 1 Proportion of children born in Norway in the period 2008–19 who were diagnosed with ankyloglossia within four weeks of birth and who underwent tongue-tie surgery. Data retrieved from the Norwegian Patient Register.

Lingual frenulum

The lingual frenulum is a fold of mucous membrane that helps stabilise the base of the tongue by binding the tongue to the floor of the mouth (5, 13, 14). Ankyloglossia occurs most frequently as an isolated anatomical variation in which the lingual frenulum is so short, hypertrophic or tight that it interferes with the free movement of the tongue (2, 5). The lingual frenulum may either be attached too close to the tip of the tongue and too far forward towards the inferior alveolar ridge, or it may be attached in a more posterior position on the tongue and the floor of the mouth, but be so short as to impede movement. When the tongue is lifted, the tip of the tongue may form a heart

shape (2). Some classify ankyloglossia as a congenital malformation of the genioglossus muscles (15). The condition has been assigned its own ICD-10 code, Q38.1 Ankyloglossia (16).

The concept of 'posterior lingual frenulum' is controversial (4, 17, 18). Some maintain that the term describes the functional symptoms associated with tongue-tie, without necessarily requiring a visibly tight or short lingual frenulum (3, 18). According to the guidelines of the Norwegian Society of Pediatricians, 'posterior lingual frenulum' simply means a somewhat thicker submucosa in the posterior part of the lingual frenulum; the guidelines emphasise that there is only a single lingual frenulum (19). The term can also be misleading because the reasons for reduced tongue mobility may be complex, and not necessarily related to the lingual frenulum itself (17).

No specific embryological cause of ankyloglossia has been identified. It has been suggested that the short mucosa and increased fibromuscular tissue in the midline may result from insufficient development of the anterior tongue combined with incomplete apoptosis of the anteromedial lingual prominence and overfusion of the lateral lingual prominences (8, 20).

One of the functions of the tongue is to enable the infant to latch onto the mother's breast (21). Ultrasound examinations of breastfeeding infants suggest that good tongue mobility and the ability to create a vacuum are necessary for effective breastfeeding (22–25). An overly tight lingual frenulum may lead to difficulties by restricting the movement of the tongue (5, 13).

«We believe a more cautious approach to surgical intervention is warranted than the trend we see today»

The emphasis placed on symptoms of ankyloglossia differs depending on the age of the child (2, 3). The main issue in the neonatal period can be difficulty with breastfeeding, although the majority of children with tongue-tie do seem able to breastfeed normally (3). Several studies have examined the association between tongue-tie and breastfeeding problems, and typically describe poor latching, pain during breastfeeding, and sore nipples (5, 9, 26). These issues can in turn lead to impaired milk ejection, reduced milk production, clogged milk ducts and mastitis (8, 10, 21, 27). Tongue-tie alone does not appear able to fully explain these problems, but must be viewed in connection with other factors, including characteristics of the mother's breast (28).

Breastfeeding difficulties can manifest in various ways. Poor latching can lead to the infant losing its grip during breastfeeding. This may result in the child making 'clicking' sounds when the vacuum disappears, or in prolonged breastfeeding, irritability or poor weight gain (8, 10, 21). The extent to which ankyloglossia contributes to these symptoms is disputed, but they are included in several sets of ankyloglossia diagnostic criteria (Appendix 1). Tongue-tie does not appear to affect the ability to bottle-feed, probably because the infant uses a different technique to suck from a bottle than from the breast (3).

Prevalence and criteria

The extensive variation in the reported prevalence of ankyloglossia reflects the differing diagnostic criteria that are used. There is no consensus on either definition or grading system. Interpretation is also complicated by the fact that difficulties with breastfeeding often have other causes. In one study, the condition was diagnosed in 3.2 % of breastfed neonates within 2 days of birth (9). In neonates referred because of breastfeeding problems, the prevalence of tongue-tie varies across studies from 12.8 % to 56 % (9, 29, 30). The large increase in prevalence in Norway may be due to increased focus on the condition, previous under-reporting or a tendency to overdiagnose in recent years (Figure 1).

Prevalence beyond early infancy has been little studied and is thus uncertain, but it appears to decrease (31–33). This may be because the condition has less clinical significance once the child is no longer breastfed, or it may be because growth of the mouth and tongue leads to anatomical and functional changes. Apart from problems with breastfeeding, no definite association has been established between tongue-tie and any other symptom (including difficulties with pronunciation) (34, 35).

«Several attempts have been made to devise classification and assessment criteria for infants, but to date there are no universally accepted criteria for use in diagnosis or treatment recommendations»

Several attempts have been made to devise classification and assessment criteria for infants, but to date there are no universally accepted criteria for use in diagnosis or treatment recommendations. Decisions are therefore made on different bases (3, 4, 8, 10). An overview of existing assessment criteria and indications for treatment is provided in Appendix 1.

Management options

Breastfeeding guidance and support should be attempted first, and may reduce the need for surgery (36, 37). The most common surgical intervention in neonates is frenulotomy, often referred to as 'clipping'. The procedure is performed using scissors or a knife, with or without local anaesthesia. Frenulectomy (excision of the frenulum), frenuloplasty and laser treatment are also used (8, 22). There is currently little evidence available on the effectiveness of non-invasive therapies, such as physiotherapy, tongue stretching or craniosacral therapy (8, 38).

In recent years, two systematic reviews and a Cochrane review have been published on the effectiveness of frenulotomy for the treatment of difficulties with breastfeeding (5, 38, 39). The reviews are based on randomised clinical studies and on systematic literature searches for randomised trials and cohort studies. All three reviews emphasise that the studies included were of poor quality and had methodological weaknesses,

including small sample sizes and a lack of randomisation. A greater proportion of the mothers of treated infants reported a reduction in pain during breastfeeding in the short-term. Little is known about the long-term effects.

Frenulotomy is considered a largely safe procedure, but bleeding, infection, damage to the tongue and the submandibular ducts and recurrence of symptoms may occur (3, 40). Concerns have also been raised over the pain experienced by the infant during and after the procedure (41). The reviews note that there is a lack of research on the optimal time for frenulotomy, as well as on effective pain relief and the effects of frenulotomy on milk production and the duration of breastfeeding (5).

Guidelines

An overview of the advice and guidelines published by different countries and organisations is presented in Appendix 2. Many of the guidelines emphasise that their own recommendations are weak because they are based on studies with poor quality evidence. The majority recommend that breastfeeding guidance and support should be provided first, and that frenulotomy may then be considered if this proves insufficient and the diagnostic criteria are met. There is little consensus on which assessment criteria should be used, and several groups call for diagnostic criteria to be established so that clear guidelines can be produced (5, 8).

«When there is little evidence that a more radical treatment is better than a conservative one, we believe it is best to choose the option that is least invasive and painful for the child»

In 2021, the Norwegian National Advisory Unit on Breastfeeding published guidance on the diagnosis and treatment of tongue-tie in infants (42). Here, too, the lack of high-quality evidence for the effectiveness of treatment is acknowledged. Nevertheless, the guidance is in our opinion notably proactive in recommending the clipping of tongue-tie. The symptoms in mother and child that are listed as potentially being due to tongue-tie are so extensive and non-specific that the majority of breastfeeding mothers may feel they have them. For example, problems such as pain during breastfeeding, incomplete emptying of the breast, or that the child has difficulty achieving and maintaining a latch or falls asleep on the breast before completing a feed, are very common and usually temporary in connection with the initiation of breastfeeding.

We fear this guidance may lead to a further increase in pressure to clip tongue-tie. We gain little reassurance from the authors' statement that 'the fact that there is no high quality evidence documenting the effectiveness of treatment does not mean that the treatment does not help' (42). When faced with a choice between two treatments, where there is little evidence that the more radical option is better than the conservative one, we believe it best to choose the option that is least invasive and painful for the child.

Conclusion

The majority of children with tongue-tie do not have difficulties with breastfeeding, and children who have difficulties with breastfeeding often do not have tongue-tie. Good breastfeeding guidance and support must always be offered before surgery is considered. Although the evidence for the effectiveness of clipping is limited, the majority of systematic reviews and guidelines suggest that clipping can be performed in an attempt to reduce breastfeeding problems if tongue-tie has also been diagnosed. However, there are no good studies on the long-term effects of surgery. An irreversible procedure on an individual who is not competent to consent should only be performed after a thorough assessment of the procedure's benefits versus risks, as well as the pain that may be experienced by the neonate. There is scarcely a surgical procedure in Norway that is now performed more frequently in the neonatal period than the clipping of tongue-tie. The increase seen in recent years calls for additional caution to avoid overdiagnosis and overtreatment.

This article contains information from the Norwegian Patient Register. The authors are solely responsible for the interpretation and presentation of the information provided, and the manager of the register is not responsible for analyses or interpretations based on this information. This article has been peer-reviewed.

LITERATURE

1. Jin RR, Sutcliffe A, Vento M et al. What does the world think of ankyloglossia? *Acta Paediatr* 2018; 107: 1733–8. [PubMed][CrossRef]
2. Lalakea ML, Messner AH. Ankyloglossia: does it matter? *Pediatr Clin North Am* 2003; 50: 381–97. [PubMed][CrossRef]
3. Isaacson GC. Ankyloglossia (tongue-tie) in infants and children. UpToDate. <https://www.uptodate.com/contents/ankyloglossia-tongue-tie-in-infants-and-children> Accessed 27.7.2021.
4. Messner AH, Walsh J, Rosenfeld RM et al. Clinical consensus statement: ankyloglossia in children. *Otolaryngol Head Neck Surg* 2020; 162: 597–611. [PubMed][CrossRef]
5. O'Shea JE, Foster JP, O'Donnell CP et al. Frenotomy for tongue-tie in newborn infants. *Cochrane Database Syst Rev* 2017; 3: CD011065. [PubMed]
6. Lisonek M, Liu S, Dzakpasu S et al. Changes in the incidence and surgical treatment of ankyloglossia in Canada. *Paediatr Child Health* 2017; 22: 382–6. [PubMed][CrossRef]
7. Walsh J, Links A, Boss E et al. Ankyloglossia and lingual frenotomy: national trends in inpatient diagnosis and management in the United States 1997–2012. *Otolaryngol Head Neck Surg* 2017; 156: 735–40. [PubMed][CrossRef]

8. Walsh J, Tunkel D. Diagnosis and treatment of ankyloglossia in newborns and infants – A review. *JAMA Otolaryngol Head Neck Surg* 2017; 143: 1032–9. [PubMed][CrossRef]
9. Ballard JL, Auer CE, Khoury JC. Ankyloglossia: assessment, incidence, and effect of frenuloplasty on the breastfeeding dyad. *Pediatrics* 2002; 110: e63. [PubMed][CrossRef]
10. Segal LM, Stephenson R, Dawes M et al. Prevalence, diagnosis, and treatment of ankyloglossia: methodologic review. *Can Fam Physician* 2007; 53: 1027–33. [PubMed]
11. Messner AH, Lalakea ML. Ankyloglossia: controversies in management. *Int J Pediatr Otorhinolaryngol* 2000; 54: 123–31. [PubMed][CrossRef]
12. Power RF, Murphy JF. Tongue-tie and frenotomy in infants with breastfeeding difficulties: achieving a balance. *Arch Dis Child* 2015; 100: 489–94. [PubMed][CrossRef]
13. Dahl H, Rinvik E. Fordøyelsesorganene. I: *Menneskets funksjonelle anatomi*. 3. utg. Oslo: Cappelen Damm, 2010: 601–2.
14. Mills N, Pransky SM, Geddes DT et al. What is a tongue tie? Defining the anatomy of the in-situ lingual frenulum. *Clin Anat* 2019; 32: 749–61. [PubMed][CrossRef]
15. Ferrés-Amat E, Pastor-Vera T, Rodríguez-Alessi P et al. Management of ankyloglossia and breastfeeding difficulties in the newborn: Breastfeeding sessions, myofunctional therapy, and frenotomy. *Case Rep Pediatr* 2016; 2016: 3010594. [PubMed][CrossRef]
16. Direktoratet for e-helse. ICD-10. Den internasjonale statistiske klassifikasjonen av sykdommer og beslektede helseproblemer. <https://finnkode.ehelse.no/#icd10/0/0/0/2620294.1> Accessed 25.6.2021.
17. Douglas PS. Rethinking "posterior" tongue-tie. *Breastfeed Med* 2013; 8: 503–6. [PubMed][CrossRef]
18. Hong P, Lago D, Seargeant J et al. Defining ankyloglossia: a case series of anterior and posterior tongue ties. *Int J Pediatr Otorhinolaryngol* 2010; 74: 1003–6. [PubMed][CrossRef]
19. Norsk barnelegeforening. *Pediatriveileder: Stramt tungebånd hos nyfødte*. <https://www.helsebiblioteket.no/pediatriveiledere?menuitemkeylev1=11574&key=262401> Accessed 25.6.2021.
20. Schoenwolf G, Bleyl S, Brauer P et al. Development of the pharyngeal apparatus and face. I: *Larsen's Human Embryology*. 5. utg. Philadelphia, PA: Elsevier/Churchill Livingstone, 2015: 458–60.
21. Hooda A, Rathee M, Yadav S et al. Ankyloglossia: A review of Current Status. *The Internet Journal of Otorhinolaryngology* 2009; 12: 1–8.

22. Smith WL, Erenberg A, Nowak A et al. Physiology of sucking in the normal term infant using real-time US. *Radiology* 1985; 156: 379–81. [PubMed][CrossRef]
23. Monaci G, Woolridge M. Ultrasound video analysis for understanding infant breastfeeding. *International Congress of Image Processing (ICIP) Brussels: IEEE*, 2011. <https://ieeexplore.ieee.org/document/6115802> Accessed 27.7.2021.
24. Elad D, Kozlovsky P, Blum O et al. Biomechanics of milk extraction during breast-feeding. *Proc Natl Acad Sci U S A* 2014; 111: 5230–5. [PubMed][CrossRef]
25. Geddes DT, Langton DB, Gollow I et al. Frenulotomy for breastfeeding infants with ankyloglossia: effect on milk removal and sucking mechanism as imaged by ultrasound. *Pediatrics* 2008; 122: e188–94. [PubMed][CrossRef]
26. Hogan M, Westcott C, Griffiths M. Randomized, controlled trial of division of tongue-tie in infants with feeding problems. *J Paediatr Child Health* 2005; 41: 246–50. [PubMed][CrossRef]
27. Kent JC, Ashton E, Hardwick CM et al. Nipple pain in breastfeeding mothers: incidence, causes and treatments. *Int J Environ Res Public Health* 2015; 12: 12247–63. [PubMed][CrossRef]
28. Ammehjelpen. Stramt eller kort tungebånd. <https://ammehjelpen.no/tungeband/> Accessed 25.6.2021.
29. Ferrés-Amat E, Pastor-Vera T, Rodriguez-Alessi P et al. The prevalence of ankyloglossia in 302 newborns with breastfeeding problems and sucking difficulties in Barcelona: a descriptive study. *Eur J Paediatr Dent* 2017; 18: 319–25. [PubMed]
30. Campanha SMA, Martinelli RLC, Palhares DB. Association between ankyloglossia and breastfeeding. *CoDAS* 2019; 31: e20170264. [PubMed][CrossRef]
31. Sawyer DR, Taiwo EO, Mosadomi A. Oral anomalies in Nigerian children. *Community Dent Oral Epidemiol* 1984; 12: 269–73. [PubMed][CrossRef]
32. Koay CL, Lim JA, Siar CH. The prevalence of tongue lesions in Malaysian dental outpatients from the Klang Valley area. *Oral Dis* 2011; 17: 210–6. [PubMed][CrossRef]
33. Sedano HO, Carreon Freyre I, Garza de la Garza ML et al. Clinical orodental abnormalities in Mexican children. *Oral Surg Oral Med Oral Pathol* 1989; 68: 300–11. [PubMed][CrossRef]
34. Webb AN, Hao W, Hong P. The effect of tongue-tie division on breastfeeding and speech articulation: a systematic review. *Int J Pediatr Otorhinolaryngol* 2013; 77: 635–46. [PubMed][CrossRef]
35. Chinnadurai S, Francis DO, Epstein RA et al. Treatment of ankyloglossia for reasons other than breastfeeding: a systematic review. *Pediatrics* 2015; 135: e1467–74. [PubMed][CrossRef]
36. Dixon B, Gray J, Elliot N et al. A multifaceted programme to reduce the rate of tongue-tie release surgery in newborn infants: Observational study. *Int J Pediatr*

Otorhinolaryngol 2018; 113: 156–63. [PubMed][CrossRef]

37. Caloway C, Hersh CJ, Baars R et al. Association of feeding evaluation with frenotomy rates in infants with breastfeeding difficulties. *JAMA Otolaryngol Head Neck Surg* 2019; 145: 817–22. [PubMed][CrossRef]

38. Francis DO, Krishnaswami S, McPheeters M. Treatment of ankyloglossia and breastfeeding outcomes: a systematic review. *Pediatrics* 2015; 135: e1458–66. [PubMed][CrossRef]

39. Canadian Agency for Drugs and Technologies in Health. Frenectomy for the correction of Ankyloglossia: A Review of clinical Effectiveness and Guidelines. Ottawa, ON: CADTH Rapid Response Report, 2016.

40. Sundhedsstyrelsen. Undersøgelse og behandling af ankyloglossi hos ammede spædbørn. Nasjonal klinisk retningslinje. <https://www.sst.dk/da/Opgaver/Patientforloeb-og-kvalitet/Nationale-kliniske-retningslinjer-NKR/Puljefinansierede-NKR/Undersoegelse-og-behandling-af-ankyloglossi-hos-ammede-spaedboern> Accessed 25.6.2021.

41. Eriksson M, Johansson S, Nilsson S et al. «Socialstyrelsen behøver utreda tungebandsklipp». *Dagens Medicin* 16.6.2021. https://www.dagensmedicin.se/opinion/debatt/socialstyrelsen-behoever-utreda-tungebandsklipp/?fbclid=IwAR3XXT3ZlAhnzRdj5Fj7E15oRQdcKPITCfN34sTP2_cktWMXZliPQcbXfMY Accessed 25.6.2021.

42. Nasjonal kompetansetjeneste for amming. Stramt tungebånd – Veileder for diagnostikk og behandling av stramt tungebånd hos spedbarn. Oslo: Oslo universitetssykehus, 2021. <https://oslo-universitetssykehus.no/seksjon/Nasjonalkompetansetjeneste-for-ammings/Documents/Veileder%20Stramt%20tungebaend.pdf> Accessed 25.6.2021.

Publisert: 27. August 2021. Tidsskr Nor Legeforen. DOI: 10.4045/tidsskr.21.0515

Received 25.6.2021, first revision submitted 7.7.2021, accepted 27.7.2021.

Copyright: © Tidsskriftet 2026 Downloaded from tidsskriftet.no 10 July 2026.