
Scabies burrow under a dermatoscope

IMAGES IN MEDICINE

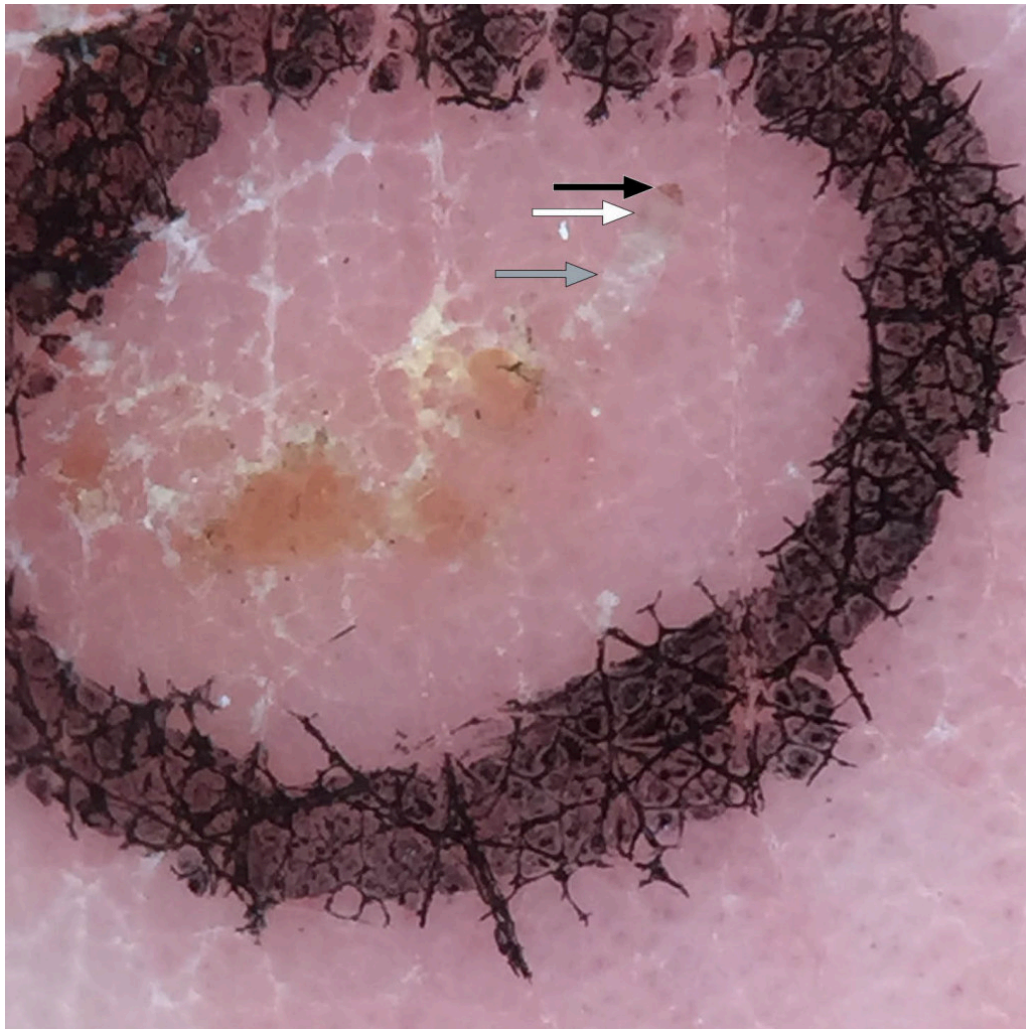
HELGE DANIELSEN

E-mail: hedan@online.no

Dermatology Clinic

Voss Norway

Helge Danielsen is a specialist in dermatology and venereology, contract specialist and member of the Norwegian Institute of Public Health's working group to combat scabies. The author has completed the ICMJE form and reports no conflicts of interest.



The dermatoscope is the dermatologist's stethoscope. It is used for diagnosing pigmented lesions, benign and malignant tumours and inflammatory dermatoses, and in connection with infestations. The dermatoscope may also be useful to general practitioners, amongst other things for scabies diagnosis ([1](#), [2](#)).

A scabies mite is 0.2–0.5 mm in diameter. It burrows a track in the epidermis, in the stratum corneum, where it lays its eggs. Both mite and burrows are easily visualised with a dermatoscope which provides x 10 magnification.

Once we have found a possible or definite scabies track under the magnifying lamp, we see it clearly with the dermatoscope (grey arrow). At the end of the scabies burrow we see a dark triangle (black arrow). This is the forepart of the mite, with head, mouth and front legs. The find is called the 'Delta' sign, with reference to the Greek letter Δ . The rear portion of the mite's body is only just perceptible, because it is light-coloured and translucent (white arrow). The remainder of the track winds where the mite has burrowed through the epidermis.

The delta sign is more difficult to see on a dark skin, but the dermatoscope enables good visualisation of the mite's burrow nonetheless.

As with all procedures, this requires training, but once you have found a track and mite with a dermatoscope, it is easy to recognise again. The method showed a sensitivity of over 90 % in one study, also among doctors with limited experience of dermatoscopy. The number of scabies patients diagnosed through normal clinical assessment increased considerably when a dermatoscope was used (1). Once the mite has been located with a magnifying lamp or dermatoscope, it can be removed and placed under a microscope. This results in a definitive diagnosis. The method, with a dental probe under a dermatoscope, is shown on the video.

The patient has consented to the publication of the article.

The article has been peer-reviewed.

LITERATURE

1. Dupuy A, Dehen L, Bourrat E et al. Accuracy of standard dermoscopy for diagnosing scabies. *J Am Acad Dermatol* 2007; 56: 53–62. [PubMed][CrossRef]
2. Fox G. Diagnosis of scabies by dermoscopy. *BMJ Case Rep* 2009; 2009: bcr0620080279. [PubMed][CrossRef]

Publisert: 26. October 2020. Tidsskr Nor Legeforen. DOI: 10.4045/tidsskr.20.0792
Copyright: © Tidsskriftet 2026 Downloaded from tidsskriftet.no 5 July 2026.