Tidsskriftet Tidsskrift for Den norske legeforening

A young man with convulsive laughter

EDUCATIONAL CASE REPORT

ANE TOFT

Department of Østmarka
St. Olavs Hospital, Trondheim University Hospital, Trondheim, Norway
Ane Toft is a senior consultant and specialist in psychiatry.
The author has completed the ICMJE form and declares no conflicts of interest.

TORE WERGELAND MEISINGSET

Department of Neurology and Neurophysiology
St. Olavs Hospital, Trondheim University Hospital, Trondheim, Norway
Tore Wergeland Meisingset is a specialty registrar in neurology, postdoctoral fellow and associate professor.
The author has completed the ICMJE form and declares no conflicts of interest.

SVERRE GEORG SÆTHER

E-mail: sverrege@gmail.com
Nidaros District Psychiatric Centre
St. Olavs Hospital, Trondheim University Hospital, Trondheim, Norway
Sverre Georg Sæther PhD is a senior consultant and specialist in psychiatry. His PhD thesis concerned systemic and neuronal antibodies in acute psychiatric disorders.
The author has completed the ICMJE form and declares the following conflicts of interest: He owns shares in Nordic Nanovector, which develops drugs for haematological malignancies. The company has no connection with the drugs discussed in this case report.

BACKGROUND

Steroid-responsive encephalopathy associated with autoimmune thyroiditis (SREAT) can manifest with a wide range of neurological and psychiatric symptoms.

CASE PRESENTATION

A previously healthy man in his late twenties was admitted several times over the course of half a year. He had acute episodes of reduced consciousness, involuntary movements and psychotic symptoms (e.g. hallucinations and delusions). Initial examinations were normal except for a positive urine drug screen (tetrahydrocannabinol), and the patient was diagnosed with cannabinoid intoxication. During the next admission cerebrospinal fluid analysis showed mild pleocytosis. Screening for anti-neuronal antibodies was negative, but anti-thyroid peroxidase antibodies were detected in serum and cerebrospinal fluid. He was successfully given steroid treatment on a tentative diagnosis of SREAT, but relapsed when the steroids were discontinued. After receiving a prolonged steroid treatment with gradual dose reduction over a year, he remains symptom-free 18 months after treatment discontinuation.

INTERPRETATION

The diagnostic delay might have been mitigated with an earlier inclusion of neuroimmunological disorders in the differential diagnosis. Unexplained pleocytosis in the cerebrospinal fluid in the presence of paroxysmal neuropsychiatric symptoms should trigger an investigation that includes autoimmune encephalopathies.

A man was hospitalised several times with loss of consciousness accompanied by involuntary movements. He would then experience confusion, with episodes of visual and auditory hallucinations. His condition was attributed on several occasions to substance use, but eventually a rare disease was suspected, for which effective treatment is available.

The partner of a previously healthy man in his twenties came home one day to an intense and unpleasant smell. She followed traces of vomit into the bedroom where she found her partner on the floor, unresponsive and agitated, and soiled with vomit and urine.
When the ambulance arrived, the man was still unresponsive (score of 6 on the Glasgow Coma Scale (GCS)). He was making large, involuntary arm movements, which ceased when he was intubated and sedated on the spot. Upon arrival at Acute Admissions, he was afebrile, had a pulse of 60 beats/min and was hypertensive with blood pressure of 240/100 mm Hg. The results of other clinical tests were normal.

In cases of vomiting, hypertension and unconsciousness, it is important to quickly exclude conditions that cause elevated intracranial pressure or that otherwise affect the brainstem. At the same time, the possibility of intoxication or a metabolic disorder must be investigated. Unconsciousness with subsequent confusion may also be seen following generalised tonic-clonic seizures and requires a similar assessment of precipitating factors (1).

Arterial blood gas analysis showed pH 7.32 (7.38–7.46), pCO_2 5.9 (4.3–6.0 kPa), pO_2 56.6 (11.0–14.4 kPa), and lactate 2.2 (0.5–2.2 mmol/l). CT arteriography and brain MRI showed normal findings. Blood tests showed elevation of leukocytes to $16.9 \cdot 10^9$/l ($4.1–9.8 \cdot 10^9$/l) and creatine kinase 483 U/l (50–400 U/l), whereas haemoglobin, platelets, C-reactive protein and liver and kidney tests were normal. In the cerebrospinal fluid, total protein was slightly elevated, to 0.77 g/l (0.15–0.50 g/l), but the cell count was normal. See Figure 1 for a chronological overview of the test results.

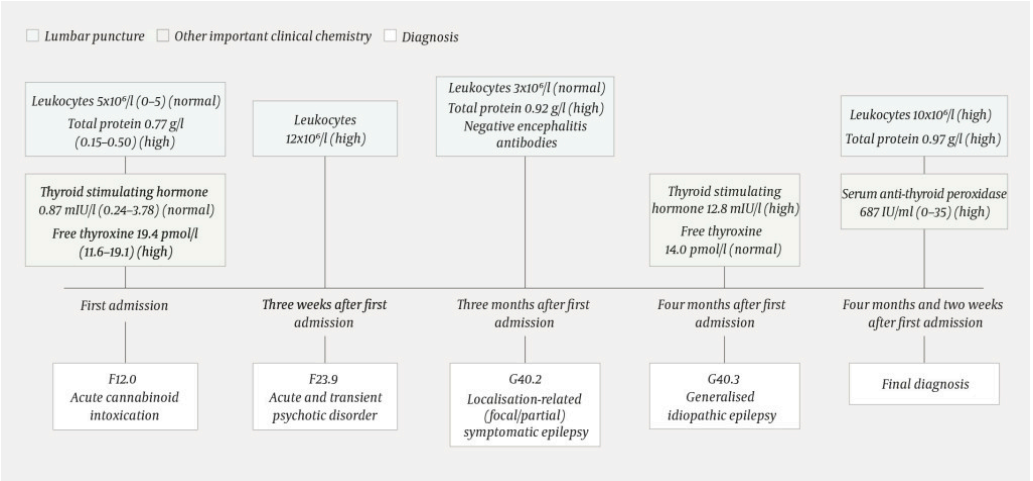

Figure 1 Chronological overview of test results. N = normal values, H = high values, tot = total.

The next day, the patient was awakened and extubated in the intensive care unit before being transferred to a ward. He was able to answer questions but had a long response latency. He was oriented to place and situation, but not to time. It emerged that he had smoked cannabis for eight years and had also been smoking immediately prior to his admission.
Three days after admission, EEG showed generalised, non-specific abnormalities most pronounced frontotemporally, but no epileptiform activity. Free thyroxine was slightly elevated at 19.4 pmol/l (11.6–19.1 pmol/l), but thyroid-stimulating hormone levels were normal. A urine specimen tested positive for tetrahydrocannabinol (THC).
That same day, the patient was ambulant and doing well and was discharged with a diagnosis of acute cannabinoid intoxication. An outpatient EEG was scheduled.

The involuntary movements had been observed by a neurologist who did not consider them to be the result of an epileptic seizure. Cannabinoid intoxication rarely requires hospitalisation, but intense anxiety, psychosis and cardiovascular effects may occur in severe cases (2).

Three weeks after the first admission, the patient suddenly began to speak incomprehensibly and attempted to dress himself in his bedding. In Acute Admissions, he was photophobic, agitated and had visual and auditory hallucinations. He was sent to an emergency psychiatric ward with suspected cannabis-induced psychosis. However, the doctor on duty in the psychiatric department did not consider the patient's sudden onset of fluctuating symptoms with disorientation and multimodal hallucinations to be typical of a psychotic disorder. The patient was therefore sent back to the medical department.

Box 1 shows clinical characteristics that should increase suspicion that psychotic symptoms have an organic origin.

Box 1 Clinical characteristics that should increase suspicion that psychotic symptoms have an organic origin (modified from Keshavan and Kaneko (3))

Atypical presentation

Late age of onset in previously healthy patient

Acute onset

Severe disorientation and/or confusion

Catatonia

Presence of visual or multimodal hallucinations

Fluctuating symptoms

Back in the medical department, blood and cerebrospinal fluid samples were obtained under light propofol anaesthesia. The leukocyte count was slightly elevated in the cerebrospinal fluid ($12 \cdot 10^6/l$ ($<5 \cdot 10^6/l$)) and the urine was still positive for tetrahydrocannabinol. The results of other tests were normal. The next day he appeared much better, but remembered nothing from the previous days.

On the day of discharge, he was cooperative and was no longer agitated. He denied having engaged in substance use since his previous hospitalisation. Acute transient psychosis was diagnosed and an outpatient EEG was scheduled.

Cerebrospinal fluid pleocytosis suggests a neuroinflammatory condition, and it is important to rule out autoimmune and infectious encephalitis. Testing for autoimmune encephalitis (anti-neuronal antibodies) was not performed at this stage, however, probably owing to the patient's rapid recovery.

Three months after his first admission, the patient was found unconscious again, this time with a bicycle on top of him. When the ambulance arrived, he had psychomotor agitation and gurgling respiration. Upon arrival at hospital, he scored 7 on the Glasgow Coma Scale, and CT multitrauma, initial blood tests and blood gas analysis were normal.

The on-duty neurologist examined the patient, and found him to be unresponsive with involuntary movements, striatal toe and a clear bilateral extensor plantar reflex (see video). During his two previous hospitalisations, the patient had shown a flexor plantar reflex. There were no lateralising signs and brainstem reflexes were intact.

The patient showed bilateral and axial hyperkinetic movements with ballistic features in the upper extremities (see video). Similar movements had also been described during his first hospitalisation. Episodic seizures with loss of consciousness would typically suggest epilepsy, whereas the hyperkinetic movements suggested a movement disorder. Movement disturbances accompanied by altered consciousness are also seen in a wide variety of toxic-metabolic encephalopathies (4). Episodic presentation may be triggered by hypoglycaemia (5) or by repeated exposures to toxins.

It was unclear how to interpret the situation, but a decision to treat the condition as non-convulsive status epilepticus was made. An intravenous bolus of fosphenytoin 1200 mg had no effect, but the involuntary movements lessened after an intravenous bolus of levetiracetam 3000 mg. A few hours after admission, the patient was sitting upright in bed, swaying from side to side, without responding to verbal stimuli. EEG showed moderate to pronounced generalised non-specific abnormalities. The following day he was responsive, but confused.

Non-convulsive status epilepticus is marked by prolonged epileptic seizures without prominent convulsions (6). The condition shows a broad spectrum of clinical presentations, and a definitive diagnosis requires an EEG to be performed during a seizure (7). In the event of uncertainty over interpretation of the EEG, it may be necessary to attempt treatment with intravenous antiepileptic drugs. A number of other conditions may resemble non-convulsive status epilepticus, including toxic and metabolic encephalopathies (e.g. in cases of substance use) (6).

To rule out intoxication as the cause of the recurrent seizures, extended screening with Q-TOF analysis was performed. The results suggested no recent use of illicit substances.
The patient's family stated that he had been noticeably confused after his previous admissions. They felt that the hospital was focusing excessively on the patient's substance use, and they were concerned about his welfare. Serum and cerebrospinal fluid tested negative for anti-neuronal antibodies. The patient was discharged with an unchanged dose of levetiracetam 750 mg × 2 per os and an appointment at the neurological outpatient clinic.
The patient's condition was interpreted at this stage as recurrent epileptic seizures of unknown cause.

Four months after his first admission, the patient collapsed during a seizure of approximately 30 seconds duration. When the ambulance arrived, his eyes were open but he was unresponsive (GCS score 7). In Acute Admissions, he was breathing unaided but was unconscious and showed slow, twisting movements of all extremities. Diazepam 2.5 mg × 3 was administered intravenously and had a transient effect. After normal findings on a brain CT scan, he was transferred to the neurological intensive care unit. There he vomited repeatedly and showed a transient fall in oxygen saturation. Diazepam 2.5 mg was administered intravenously, along with an intravenous bolus of valproate 2 700 mg followed by infusion at 100 mg/h. During the night he showed psychomotor agitation and received several doses of intravenous diazepam 2.5–5 mg, to some effect.
When assessed on the ward the following day, he showed some ability to follow instructions but did not respond when addressed. Eventually he tried to crawl out of bed. The neurologist suspected epileptic seizures with postictal confusion.
The next day he was awake and oriented. He reported headache, dizziness and amnesia for his days in hospital. EEG showed non-specific abnormalities most pronounced frontotemporally. Thyroid-stimulating hormone was elevated for the first time in the disease course at 12.8 mIU/l (0.24–3.78 mIU/l).
The patient was diagnosed with generalised idiopathic epilepsy and was discharged with levetiracetam in tablet form 1000 mg × 2 and an appointment at the neurological outpatient clinic.
Four months and two weeks after his first admission, the patient began to laugh loudly while at a gathering, apparently in response to something that had been said. However, he then continued laughing in a strained and spasmodic manner until he suddenly stiffened and lost consciousness. In Acute Admissions he was unresponsive (GCS score 6), had gaze deviation towards the right and showed episodic involuntary arm movements. His plantar reflex was flexor. An intravenous bolus of valproate 2 700 mg was administered, followed by infusion at 100 mg/h. In the neurological intensive care unit he vomited and began to show agonal respiration with a fall in oxygen saturation to 70–80 %. At this point, the plantar reflex was extensor. The patient was sedated and intubated.

He was extubated the following day. However, he was very confused, heard gunshots and explosions outside the hospital and thought that he was in a warzone. He stared at the painting of a flower in his room and described how the flower took on new shapes and colours each time he looked at it. His symptoms fluctuated from one hour to the next. The experiences were very unpleasant for the patient, but during lucid periods he understood that they were not real.
Antibodies against thyroid peroxidase (anti-TPO) were examined for the first time and were found to be elevated in serum, 687 IU/ml (0–35 IU/ml). The cerebrospinal fluid showed a slightly elevated leukocyte count of $10 \cdot 10^6$/l (<5 $\cdot 10^6$/l) and total protein 0.97 g/l (0.15–0.50 g/l) as well as the presence of anti-TPO.
Steroid-responsive encephalopathy associated with autoimmune thyroiditis was suspected. The patient was given intravenous methylprednisolone 1 000 mg × 1 daily for five days. He appeared to improve during the treatment, reported no hallucinations, and was eventually considered to be more or less in his habitual state. He was discharged with levetiracetam 1 000 mg × 2 and valproate 600 mg × 2, both in tablet form.

Steroid-responsive encephalopathy associated with autoimmune thyroiditis (Hashimoto's encephalopathy) is a rare and controversial condition (8, 9). It was suspected on the basis of the recurrent neuropsychiatric symptoms, subclinical thyroid disease, positive anti-TPO and the lack of any other good explanation for the symptoms. Anti-TPO is present in serum in 10 % of the normal population (10). In the absence of a specific diagnostic test, an expert group proposed the following criteria for the condition in 2016 (Box 2).

Box 2 Diagnostic criteria for steroid-responsive encephalopathy associated with autoimmune thyroiditis (11).

1. Encephalopathy with seizures, myoclonus, hallucinations or stroke-like episodes
2. Subclinical or mild thyroid disease (most often hypothyroidism)
3. Brain MRI shows normal findings or non-specific changes
4. Presence of anti-thyroid antibodies (TPO, thyroglobulin)
5. Absence of well-characterised anti-neuronal antibodies in serum and cerebrospinal fluid
6. Exclusion of other causes (suggested exclusion list can be found in the appendix of Graus et al. (11))

Six months after his first admission, the patient's partner once again found him in a state of decreased consciousness. He had been complaining beforehand that he could not see anything and that he kept walking into things. In Acute Admissions, the now familiar arm movements were accompanied by twisting of the head back and forth. He later developed a

rhythmic rocking movement of his left extremity accompanied by gaze deviation upwards and to the right. He was given diazepam 10 mg intravenously and was transferred to the neurological intensive care unit.
On suspicion of steroid-responsive encephalopathy associated with autoimmune thyroiditis, treatment was initiated with methylprednisolone 1 000 mg intravenously for five days. After showing rapid improvement, the patient was discharged with tablets of levetiracetam 1 000 mg × 2, valproate 600 mg × 2 and prednisolone 60 mg × 1 with a 4-week taper.
The optimal duration of steroid treatment for steroid-responsive encephalopathy associated with autoimmune thyroiditis has yet to be examined in studies.

One week after discontinuing prednisolone, the patient suddenly began to experience word-finding difficulties. He then had a seizure during which his head turned to the left and his body became stiff and extended. Seven months and one week had now passed since his first admission. His family described a reduced level of functioning over the last few months. They reported a clear improvement following the initiation of steroid treatment, and more headaches, tremors and 'near-seizures' after discontinuation. After being hospitalised for another week, the patient was discharged with tablets of levetiracetam 1 000 mg × 2, valproate 600 mg × 2 and prednisolone 30 mg × 1.
The patient's prednisolone was slowly tapered until, one year after his last seizure, it was discontinued. Eighteen months after discontinuation, the patient remains seizure-free. He is in full-time employment and says he is gradually returning to his previous level of functioning. He continues to be prescribed levetiracetam 1 000 mg × 2 with a plan for tapering and discontinuation.

Discussion

This case report illustrates how organic brain disease can give rise to a broad spectrum of neuropsychiatric symptoms. Effective diagnostic testing is crucial for the provision of targeted treatment. Our patient's illness was suspected early on to be the result of severe substance use or a psychotic disorder.

Determining whether or not psychotic symptoms have an organic cause can be difficult Box 1). The list of organic causes of psychotic symptoms is long and includes intoxications, infections, vitamin deficiencies, epilepsies as well as autoimmune and metabolic diseases ((3). When there is clinical suspicion of an organic cause, a thorough medical history and physical examination should be supplemented with EEG, brain MRI and lumbar puncture.

In the current patient, the abrupt onset of symptoms, multimodal hallucinations, epileptic seizures, pathological EEG and ultimately neurological findings, and cerebrospinal fluid pleocytosis suggested an organic cause. Pleocytosis may also occur in cases of non-infectious status epilepticus (12), but

when antiepileptic drugs are ineffective, it suggests an inflammatory aetiology. The absence of infection and malignancy made autoimmune encephalitis a relevant differential diagnosis.

In cases of autoimmune encephalitis, antibodies bind to neurotransmitter receptors or ion channels on neurons (13). This results in inflammation or in dysfunction of the target protein. Patients usually have subacute onset of severe neuropsychiatric symptoms, which eventually evolve into seizures, involuntary movements and autonomic dysfunction. The diagnosis can be confirmed by testing for specific anti-neuronal antibodies in serum and cerebrospinal fluid.

However, in a substantial proportion of patients, no such antibodies can be detected (13, 14). When there is strong clinical suspicion of autoimmune encephalitis, it is therefore appropriate to attempt immunomodulatory therapy even if antibody tests are negative, provided that infections and malignancy have been excluded (11).

Steroid-responsive encephalopathy associated with autoimmune thyroiditis is thought to have an autoimmune aetiology. In common with autoimmune encephalitis, the condition responds well to immunomodulatory therapy, but as the term encephalopathy indicates, the inflammatory changes in the brain are often more limited.

The condition has been described previously in the Journal of the Norwegian Medical Association, concerning a woman in her sixties with episodic confusion, aphasia and myoclonus (15). Although the patients in the two case reports differ in their symptoms and disease course, both fulfil the proposed diagnostic criteria (11). The absence of seizures during periods of steroid treatment supports the diagnosis.

This case report illustrates the challenges clinicians may face in assessing patients with complex neuropsychiatric symptoms. It highlights the importance of being thorough and curious in one's approach to patients with psychotic symptoms – especially when the clinical picture is atypical of psychiatric disorders.

The patient has consented to the publication of the article and video.

The article has been peer-reviewed.

LITERATURE

1. Realfsen MS, Bø SMH, Lossius MI et al. Førstegangs generalisert tonisk-klonisk krampeanfall. Tidsskr Nor Legeforen 2015; 135: 1256–8. [PubMed] [CrossRef]

2. Turner AR, Agrawal S. Marijuana toxicity. StatPearls. Treasure Island, FL: StatPearls Publishing LLC, 2018.

3. Keshavan MS, Kaneko Y. Secondary psychoses: an update. World Psychiatry 2013; 12: 4–15. [PubMed][CrossRef]

4. Barton B, Zauber SE, Goetz CG. Movement disorders caused by medical disease. Semin Neurol 2009; 29: 97–110. [PubMed][CrossRef]

5. Gupta M, Batra A, Hirve M et al. Paroxysmal dystonic choreoathetosis with symptomatic seizures secondary to hypoglycemia caused by insulinoma. Ann Indian Acad Neurol 2011; 14: 313–5. [PubMed][CrossRef]

6. Kinney MO, Craig JJ, Kaplan PW. Hidden in plain sight: Non-convulsive status epilepticus-Recognition and management. Acta Neurol Scand 2017; 136: 280–92. [PubMed][CrossRef]

7. Kaplan PW. The clinical features, diagnosis, and prognosis of nonconvulsive status epilepticus. Neurologist 2005; 11: 348–61. [PubMed] [CrossRef]

8. Mattozzi S, Sabater L, Escudero D et al. Hashimoto encephalopathy in the 21st century. Neurology 2020; 94: e217–24. [PubMed][CrossRef]

9. Zhou JY, Xu B, Lopes J et al. Hashimoto encephalopathy: literature review. Acta Neurol Scand 2017; 135: 285–90. [PubMed][CrossRef]

10. Hollowell JG, Staehling NW, Flanders WD et al. Serum TSH, T(4), and thyroid antibodies in the United States population (1988 to 1994): National Health and Nutrition Examination Survey (NHANES III). J Clin Endocrinol Metab 2002; 87: 489–99. [PubMed][CrossRef]

11. Graus F, Titulaer MJ, Balu R et al. A clinical approach to diagnosis of autoimmune encephalitis. Lancet Neurol 2016; 15: 391–404. [PubMed] [CrossRef]

12. Malter MP, Choi S, Fink GR. Cerebrospinal fluid findings in non-infectious status epilepticus. Epilepsy Res 2018; 140: 61–5. [PubMed] [CrossRef]

13. Hermetter C, Fazekas F, Hochmeister S. Systematic review: Syndromes, early diagnosis, and treatment in autoimmune encephalitis. Front Neurol 2018; 9: 706. [PubMed][CrossRef]

14. Hacohen Y, Wright S, Waters P et al. Paediatric autoimmune encephalopathies: clinical features, laboratory investigations and outcomes in patients with or without antibodies to known central nervous system autoantigens. J Neurol Neurosurg Psychiatry 2013; 84: 748–55. [PubMed] [CrossRef]

15. Broch L, Amthor KF. En 66 år gammel kvinne med forvirring, afasi og myoklonier. Tidsskr Nor Legeforen 2010; 130: 1041–3. [PubMed][CrossRef]

Publisert: 25. May 2020. Tidsskr Nor Legeforen. DOI: 10.4045/tidsskr.19.0612
Received 26.9.2019, first revision submitted 29.1.2020, accepted 10.3.2020.
© Tidsskrift for Den norske legeforening 2026. Downloaded from tidsskriftet.no 5 July 2026.