

---

# Myocardial fibrosis

---

## REVIEW ARTICLE

TORVALD ESPELAND

E-mail: [torvald.espeland@ntnu.no](mailto:torvald.espeland@ntnu.no)

Department of Circulation and Medical Imaging,  
Norwegian University of Science and Technology  
and

Clinic of Cardiology

St. Olavs Hospital

He contributed to the conception and design of the article, to data acquisition, analysis and interpretation, literature search, preparation and revision of the manuscript, and approved the submitted version of the manuscript.

Torvald Espeland is a research fellow, specialist in internal medicine and specialty registrar in cardiology.

The author has completed the ICMJE form and reports no conflicts of interest.

IDA GJERVOLD LUNDE

Institute of Experimental Medical Research (IEMR)

Oslo University Hospital and University of Oslo

She contributed to data acquisition, analysis and interpretation, preparation and revision of the manuscript, and approved the submitted version of the manuscript.

Ida Gjervold Lunde M.Sc., PhD, is a molecular biologist and heads a research group. She is a Fellow of the European Society of Cardiology (FESC) and sits on the Translational Research Committee of the ESC. The author has completed the ICMJE form and reports no conflicts of interest.

BRAGE H. AMUNDSEN

Department of Circulation and Medical Imaging,  
Norwegian University of Science and Technology  
and

Clinic of Cardiology

St. Olavs Hospital

He contributed to the design, data acquisition, analysis and interpretation, preparation and revision of the manuscript, and approved the submitted version of the manuscript

Brage H. Amundsen is an associate professor and specialty registrar in cardiology.

The author has completed the ICMJE form and reports no conflicts of interest.

LARS GULLESTAD

Department of Cardiology

Oslo University Hospital, Rikshospitalet

He contributed to data analysis and interpretation, preparation and revision of the manuscript, and approved the submitted version of the manuscript.

Lars Gullestad is a specialist in internal medicine and cardiology and a senior consultant.

The author has completed the ICMJE form and reports no conflicts of interest.

SVEND AAKHUS

Department of Circulation and Medical Imaging,

Norwegian University of Science and Technology

and

Clinic of Cardiology

St. Olavs Hospital

He contributed to the conception and design of the article, to data acquisition, analysis and interpretation, literature search, preparation and revision of the manuscript, and approved the submitted version of the manuscript.

Svend Aakhus is a specialist in internal medicine and cardiology and a senior consultant.

The author has completed the ICMJE form and reports no conflicts of interest.

---

## **BACKGROUND**

Myocardial fibrosis arises secondary to cardiac stress or damage. This review article presents fundamental aspects of myocardial fibrosis.

## METHOD

We conducted two searches in PubMed which resulted in 417 hits. The relevance of the articles was determined on the basis of the title, abstract and, if applicable, full text. Forty-four key articles were included.

## RESULTS

Myocardial fibrosis is classified into two types: interstitial and replacement fibrosis. Fibrosis can cause adverse changes in the electrical and mechanical function of the heart, and exacerbates the prognosis of many cardiac diseases. Diagnostic imaging and biomarker research have improved the possibilities of detecting fibrosis. The ultimate goal is to develop medications that can halt or reverse myocardial fibrosis.

## INTERPRETATION

Modern diagnostics have improved the possibilities of detecting myocardial fibrosis and have increased our understanding of the significance of fibrosis in cardiac disease. The development of medicines that inhibit the development of fibrosis could be of major importance to modern cardiology.

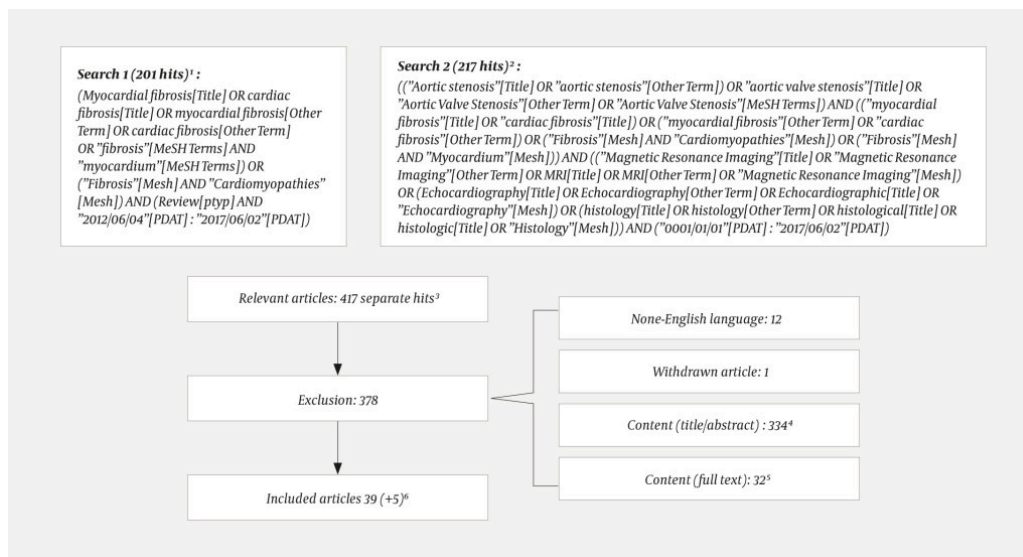
---

Myocardial fibrosis arises when the heart's fibroblasts produce collagenous scar tissue. This process may primarily be reparative, but over time often has negative consequences for the patient in the form of function impairment, morbidity and mortality. Cardiovascular disease is still the dominant cause of death in the Western world [\(1\)](#), and myocardial fibrosis arises in the course of many heart diseases. This review article first presents the pathophysiology and classification of myocardial fibrosis and methods for its detection. Some conditions in which myocardial fibrosis can be detected are then described, with the focus on aortic stenosis. Finally, future possibilities are described, with the focus on diagnostics and therapy.

---

## Method

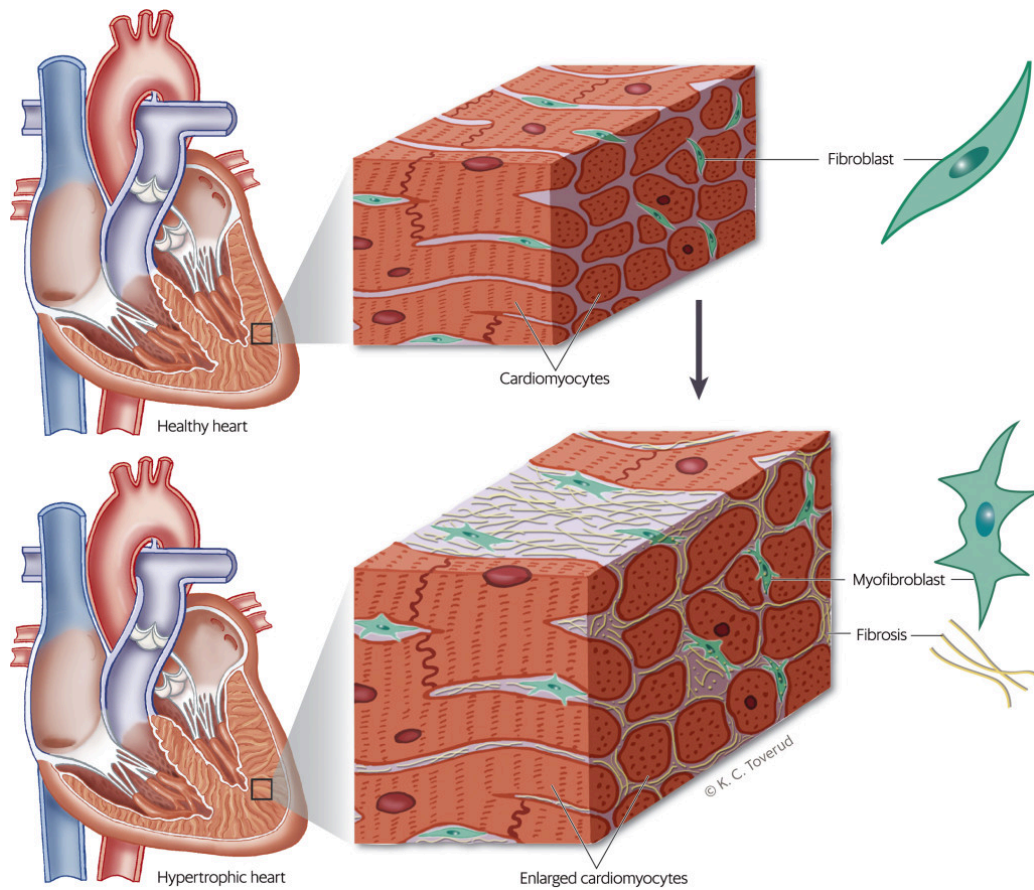
The article is based on two complementary literature searches conducted in PubMed on 2 June 2017. First, we searched for review articles from the last five years in which the terms "myocardial fibrosis" or "cardiac fibrosis" were used in the title, or occurred as MeSH terms (medical subject headings) or as *other terms* (author's tagging of article). In the second search, we combined searches for "aortic stenosis" "myocardial fibrosis" with detection methods (cardiac MRI, echocardiography or histology, with synonyms). Without defining time limits, we searched for the terms in the title, MeSH or *other terms*. The search details with number of hits, excluded and included articles, are illustrated in Figure 1. The first author excluded 378 of 417 hits on the basis of content. Five articles were added. A total of 44 articles were included, and all were read in full text.



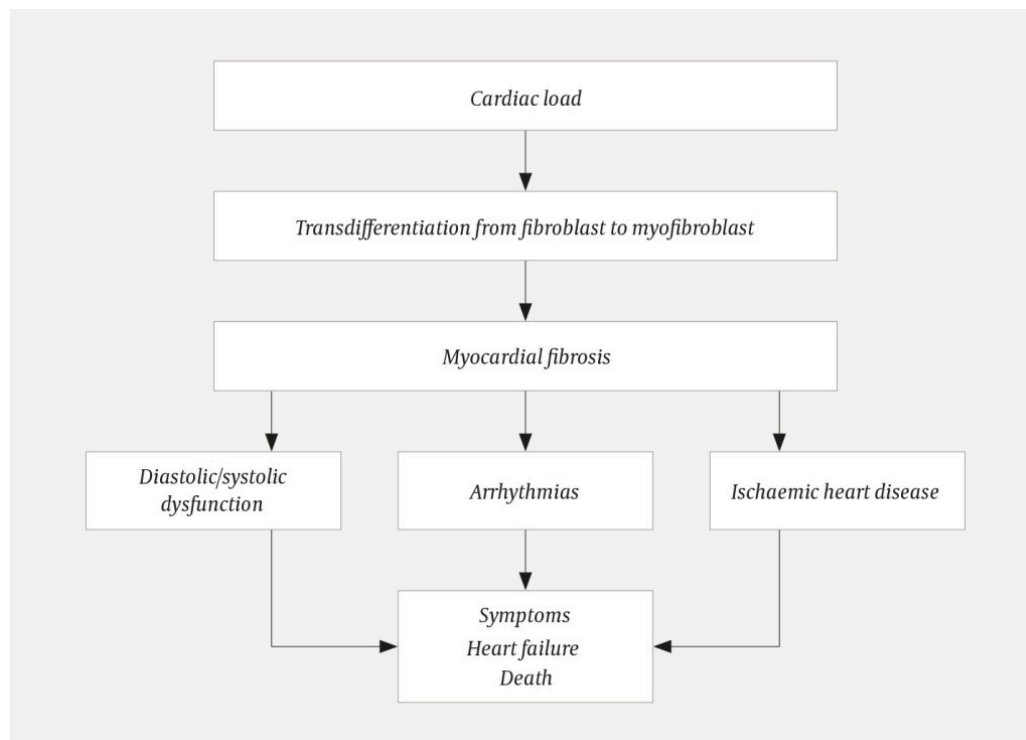
**Figure 1** The figure describes the search strategy, with exclusion and inclusion of articles. 1 In search 1 we searched for review articles from the last five years in which the term myocardial fibrosis was used and was central. 2 In search 2 we searched without defining time limits or type of article or study. We searched for articles about aortic stenosis and myocardial fibrosis and one or more detection methods (MRI, echocardiography or histology). 3 One hit was common to both searches. 4 Exclusion based on content (title or abstract) indicates that the article has an overly focused or peripheral content and that topics other than classification, pathophysiology, detection methods and central conditions are examined. There was a certain amount of selection from among similar articles. 5 Exclusion based on content (full text) indicates a narrow focus and that there has been some selection in relation to other articles that were found. Some articles were eliminated for reason of space constraints. 6 We added five articles not identified in the literature search. References 1 and 35 are not about fibrosis. References 13, 29 and 44 were found on the reference lists of articles identified through the search.

## Pathophysiology and classification

When cardiac damage and stress occur, various substances cause fibroblasts to become activated and transdifferentiate into myofibroblasts (2)–(7) (Figure 2) (8). The myofibroblasts increase the production of proteins that are deposited in the extracellular matrix (2–5). Collagen I, which accounts for about 80 % of the collagen in the myocardium, makes the myocardium stiffer and increases most in myocardial fibrosis (7, 9, 10). Cross-linking makes the collagen matrix stiffer and more difficult to break down with proteinases (2, 3, 5, 11). Fibrosis occurs as a result of net collagen production. Fibrosis restricts the supply of oxygen and nourishment to the myocardium (2, 3). Myocardial fibrosis causes electrical and structural changes that predispose patients to arrhythmias, heart failure and ischaemia (12). Figure 3 summarises the pathophysiology and consequences of myocardial fibrosis.



**Figure 2** Fibroblasts are located among cardiomyocytes, where they ensure the correct quantity and composition of extracellular matrix in the healthy heart. Pressure overload over time causes cardiac remodelling, with hypertrophy and fibrosis. Fibrosis impairs the cardiac function, and occurs when fibroblasts in the heart are activated and transdifferentiated into myofibroblasts, which increase the production of extracellular matrix. (The figure is based on Figure 1 in Herum et al. (8).)



**Figure 3** Myocardial fibrosis – pathophysiology and consequences (design based on article text).

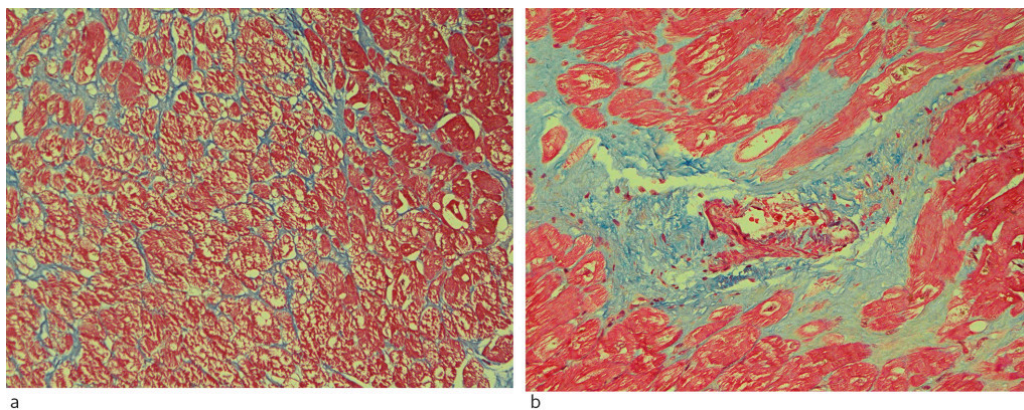
Fibrosis is classified by cause and pathoanatomy (3, 13). Interstitial (diffuse) fibrosis is characterised by diffuse spread of extracellular collagen without cardiomyocyte necrosis (8), and is believed to be reversible if early, focused treatment is administered (3, 7, 14). Diffuse fibrosis is seen in elderly people and in cardiac diseases such as aortic stenosis, cardiomyopathies and coronary heart disease without infarction (7, 15). Replacement fibrosis (scar fibrosis) is local and occurs after cardiomyocyte necrosis, for example after myocardial infarction. Replacement fibrosis is regarded as irreversible, and prevents cardiac muscle rupture after infarction (2–4), (4, 10, 13, 14, 16). However, it may also arise in the course of other diseases (3, 5, 7, 14, 16).

---

## Detection of myocardial fibrosis

### Biological specimen

Biomarkers for fibrosis can be measured in myocardial biopsies and blood tests. Myocardial biopsies are taken from explanted hearts or during myectomy, open heart surgery or catheter-based endocardial biopsy. With heart biopsies and using appropriate staining methods, histological analysis of the volume fraction of collagen is regarded as the gold standard for detection of fibrosis (7, 10, 17). Total collagen can be quantified, and the type (intrastitial or replacement) and extent of fibrosis can be described (Figure 4). Limitations are associated with possible non-representative biopsy, purely local assessment, limited amount of tissue and procedure-related risk (15), (17–19). Modern molecular biology methods can also be used, but should be validated against histology prior to clinical use (18).



**Figure 4** Myocardial biopsies from patients with hypertrophic cardiomyopathy. Masson trichrome stains connective tissue blue and myocardium red. The left-hand image (a) shows interstitial fibrosis, with thin bands of connective tissue surrounding thick (hypertrophic) cardiomyocytes. The right-hand image (b) shows replacement fibrosis where cardiomyocytes have been replaced by fibrous tissue. (Images kindly provided by Professor Helge Scott, Department of Pathology, Oslo University Hospital)

Blood biomarkers reflect cellular and molecular changes related to the quantity of fibrotic tissue (9). C-terminal propeptides of collagen I and N-terminal propeptides of collagen III are adequately validated (9), and there is optimism concerning their future clinical use. Galectin-3 stimulates the activation of myofibroblasts and the development of myocardial fibrosis (20), but the

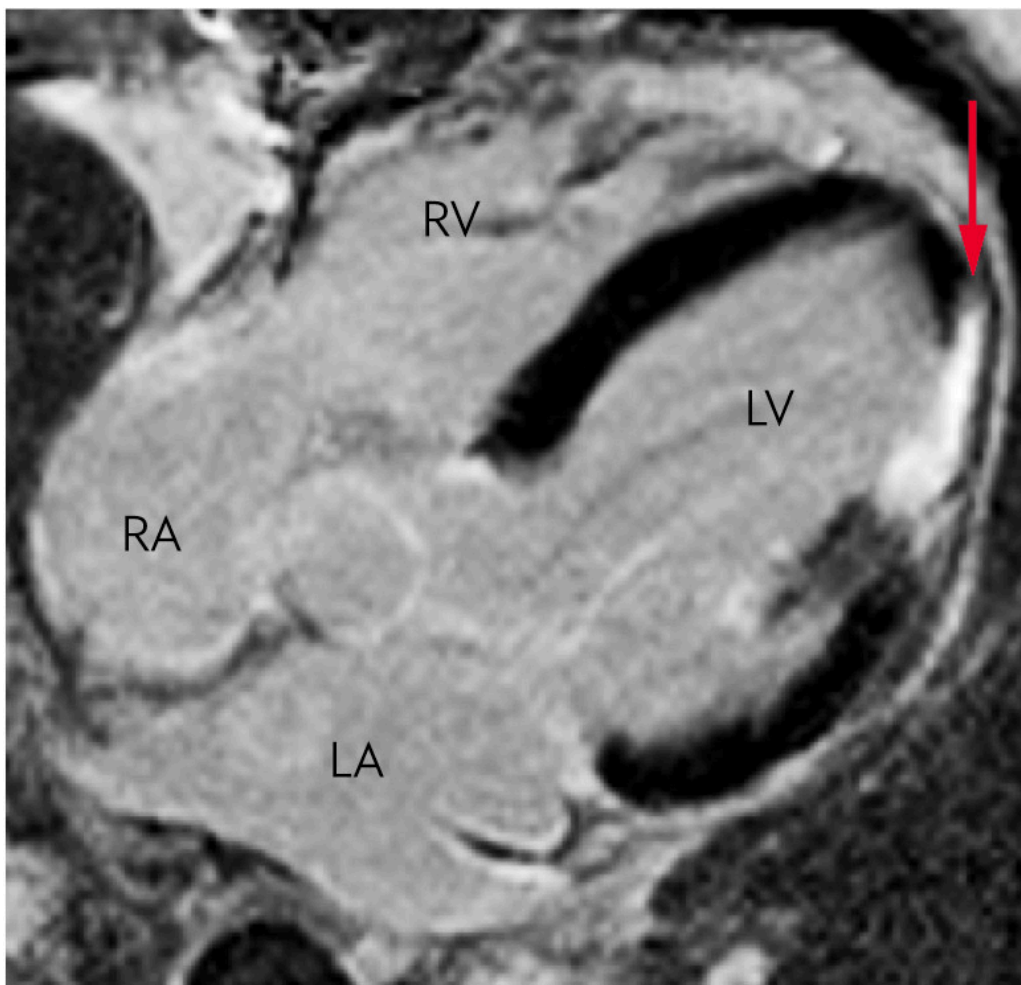
plasma concentration of galectin-3 also increases in renal disease and liver and lung fibrosis (11). Galectin-3 level is associated with mortality and a worsened prognosis in heart failure with reduced or preserved ejection fraction (3, 11).

### Cardiac MRI scan

Cardiac MRI is non-invasive in the absence of contrast injection, and maps the heart's tissue composition and function (10).

T1 relaxometry can be performed quickly without injection of contrast medium, and can therefore be carried out independently of kidney function tests (10, 16, 21). The method provides information about oedema, fibrosis (extended T1 relaxation time) and deposition diseases (7, 10, 21), and is used clinically and in research of several cardiac muscle diseases (16, 22).

In replacement fibrosis, qualitative differences can be detected in late enhancement with gadolinium-based contrast mediums (10, 18). After myocardial infarction, increased late enhancement is seen, consistent with replacement fibrosis (Figure 5). In non-ischæmic cardiac muscle diseases, late enhancement is associated with increased hypertrophy and a worsened prognosis in several conditions (23, 24). It is important to be aware that the late enhancement method is unsuitable for assessing fibrosis in cases of diffuse fibrosis with a homogenous myocardium (15, 25).



**Figure 5** Cardiac MRI scan after injection of gadolinium-based contrast. The left ventricle shows increased signal (red arrow) corresponding to anterolateral parts of the heart, consistent with replacement fibrosis. The patient suffered a myocardial

infarction with an occluded diagonal branch (exiting from the left coronary artery). LV = left ventricle, RV = right ventricle, LA = left atrium, RA = right atrium)

The heart's extracellular volume can be calculated from T1 relaxometry following gadolinium injection. In the absence of oedema or amyloid deposition, fibrosis will explain an increased extracellular volume (10, 26). The method can detect minor quantities of fibrosis and has shown better correlation with histological interstitial fibrosis than T1 relaxometry and conventional assessment of late enhancement (25). This means of calculating extracellular volume yields considerable prognostic information (10, 21). MRI determination of extracellular volume appears to be more myocardium-specific than blood biomarkers, and can be used for evaluating intervention efficacy (11).

Fibrosis as determined by MRI shows good correlation with histology (7, 10, 11, 15, 25). Heart MRI can be called a more feasible gold standard for detecting fibrosis (11, 26).

### Cardiac CT scan

Scarring and other fibrosis can be detected very accurately with CT, but in the interests of radiation hygiene, it is seldom used (19). Assessment of fibrosis with cardiac CT has shown good correspondence with cardiac MRI methods and histology (17). The method is considered if MRI is contraindicated (17) and if there are other indications for cardiac CT (27).

### Echocardiography

Diffuse fibrosis changes the wave propagation and reflection properties of the myocardium. These changes can be determined with the aid of ultrasound. Echocardiography provides additional information about the structure and function of the heart, and these parameters have been evaluated against MRI and histopathology with respect to fibrosis (6, 16). Echocardiography is cheap and readily available, but the assessment depends on image quality and operator experience (16, 18).

Table 1 sums up the strengths and weaknesses of the diagnostic methods in the detection of myocardial fibrosis.

**Table 1**

Advantages and drawbacks of different methods for detecting myocardial fibrosis. Scoring of suitability. The methods are compared on the basis of the authors' assessment.

	Histology	Blood tests	MRI	CT	Echocardiography
Direct detection of fibrosis <sup>1</sup>	+++	-	++(+)	+	+
Assessment of cardiac function	-	-	+++ <sup>2</sup>	++	+++ <sup>2</sup>
Resource-demanding (time/costs)	+++	-	++	+	+

	Histology	Blood tests	MRI	CT	Echocardiography
Availability	-	+++	+	++	++
Risk of complications	+(+) <sup>3</sup>	(+)	+	+	-
Radiation	- <sup>3</sup>	-	-	+++	-
Requires extensive training	+++	+	++(+)	++	+++

<sup>1</sup>Histology is the gold standard, while MRI is considered the non-invasive gold standard. The other methods are scored after validation against the gold standard.

<sup>2</sup>Almost as good as a gold standard for assessing cardiac function in relation to the consequences of the fibrosis.

<sup>3</sup>Presupposes tissue sampling during open heart surgery.

---

## Myocardial fibrosis in various diseases

Myocardial fibrosis is associated with increased myocardial stiffness, cardiomyocyte necrosis, arrhythmias, sudden cardiac death and unfavourable prognosis ([2, 3, 17, 18, 23, 28](#)), and plays a central part in the remodelling process that leads to heart failure ([10, 17, 26](#)). Coronary heart disease, aortic stenosis and hypertension are the most frequent causes of myocardial fibrosis ([13](#)). Aortic stenosis and hypertension result in pressure overload of the left ventricle where the increased wall stress induces hypertrophy and interstitial fibrosis ([2-4](#)). Chronic pressure overload can cause cardiomyocyte necrosis and replacement fibrosis ([22, 29](#)).

### Aortic stenosis

In aortic stenosis, histological fibrosis (interstitial and replacement) can constitute up to 30 % of the tissue volume ([14](#)). Both interstitial and replacement fibrosis can occur in the same individual. MRI studies show that interstitial fibrosis may predominate early in the course of the disease, while replacement fibrosis can be seen in up to 60 % of patients ([14, 19](#)). Fibrosis most frequently arises subendocardially and in the midwall, with greatest extension in the basal septum of the left ventricle ([10, 28, 30](#)). Local wall stress and increased wall thickness (with risk of ischaemia) may explain this.

In aortic stenosis, the extent of fibrosis is associated with symptom intensity, reduced cardiac function and physical capacity, and increased mortality ([10, 22, 23, 28](#))([28-32](#)). Extensive replacement fibrosis prior to valve surgery predicts an unfavourable post-operative outcome ([23](#)), ([29-31](#)), ([33](#)). Surgery for severe aortic stenosis is recommended if patients develop symptoms or a reduced ejection fraction, or simultaneously with other heart surgery ([34](#)). However,

preoperative assessment has challenges (27). Valve surgery should be considered before irreversible fibrosis or function impairment occurs, as early intervention may improve the prognosis for asymptomatic patients with preserved ejection fraction (23, 29). In the future, diagnostic imaging, blood biomarkers and risk calculators may help to optimise patient selection and the timing of valve surgery (31, 33).

## **Hypertension**

In hypertensive heart disease, interstitial fibrosis will translate into an unfavourable prognosis and contribute to cardiac dysfunction, coronary heart disease and arrhythmias (35). Cardiac MRI can predict future decompensation (10). The extent of fibrosis is limited in isolated hypertension, but increases with concomitant hypertrophy (36) or chronic kidney disease (16). Hypertensive patients can use inhibitors of the renin-angiotensin-aldosterone system with antifibrotic properties (36). Blood pressure reduction may cause regression of interstitial fibrosis.

## **Hypertrophic cardiomyopathy**

Hypertrophic cardiomyopathy is a genetic disease that can cause extensive myocardial fibrosis (37) (Figure 4). Fibrosis and function impairment are often greatest in the basal septum (38). High late contrast enhancement in MRI is associated with increased risk of sudden cardiac death (39). Interstitial fibrosis is more strongly associated with arrhythmias than replacement fibrosis (37).

## **Cardiac amyloidosis**

Cardiac amyloidosis, also called infiltrating interstitial fibrosis (7, 16), involves deposition of amyloid in the myocardium. In contrast to traditional myocardial fibrosis, the condition arises independently of cardiac stress or load (11). In cardiac amyloidosis, ECG and imaging may yield findings that resemble myocardial fibrosis (low voltage, hypertrophy and signs of fibrosis). Various biomarkers and cardiac MRI can distinguish between the conditions. Cardiac amyloidosis causes severe heart failure with a poor prognosis (26).

## **Ischaemic heart disease and dilated cardiomyopathy**

Non-ischaemic dilated cardiomyopathy and ischaemic heart disease are the two most frequent causes of heart failure and heart transplantation. An increased amount of replacement fibrosis, detected by MRI, is associated with a poor prognosis and severe arrhythmias (7). In dilated cardiomyopathy, fibrosis is frequently located in the midwall with patchy or diffuse distribution (7). Ischaemic replacement fibrosis occurs in transmural or subendocardial locations with regional extension corresponding to the anatomy of the coronary arteries, and can be detected by means of MRI (7). After a transmural myocardial infarction, the myocardium may appear akinetic, thinned and with higher echogenicity on an echocardiogram.

## Atrial fibrillation

In cases of atrial fibrillation, an increased amount of atrial fibrosis is seen. Severe atrial fibrosis is associated with more frequent attacks of atrial fibrillation, embolic stroke and less efficacy from antiarrhythmic drugs and radio frequency ablation (6, 40, 41). Atrial fibrosis can to a certain extent be detected by means of echocardiography and MRI, where only MRI is validated against histology. (40, 41).

## Other conditions

Fibrosis implies a poor prognosis in aortic regurgitation. One study found that the extent of fibrosis in severe aortic regurgitation resembles fibrosis in severe aortic stenosis (31).

Myocardial fibrosis is seen with severe kidney failure, particularly among patients undergoing haemodialysis treatment. Kidney transplant patients have less myocardial fibrosis than patients who undergo haemodialysis, and regression of myocardial fibrosis has been observed after transplantation (16).

Diabetic cardiomyopathy is characterised by early development of diastolic dysfunction, hypertrophy and diffuse fibrosis (42). Diabetics have higher extracellular volume judging by MRI with late enhancement, and are at increased risk of death or hospitalisation in the event of heart failure (26).

Physiological hypertrophy in connection with training and pregnancy is reversible and does not normally cause fibrosis (3). However, fibrosis can be encountered in older athletes. In cases of myocardial fibrosis in young athletes, the possibility of underlying cardiomyopathy should be considered (43).

---

## Future therapeutic possibilities

Intensive research is in progress to develop medication that reverses or halts the development of myocardial fibrosis, as it is believed that this could revolutionise the treatment of heart failure (2, 4, 11). The two main strategies for reducing fibrosis are to inhibit profibrotic or to stimulate antifibrotic molecules (5). Transforming growth factor- $\beta$  (TGF- $\beta$ ) and galectin-3 play a central part in the development of myocardial fibrosis (2, 4, 20), and fibrosis mediated by angiotensin II and aldosterone depends partly on these molecules (7, 44). Inhibition of TGF- $\beta$  and galectin-3 has exhibited an antifibrotic effect (2, 44). Inhibitors of the renin-angiotensin-aldosterone system halt the development of fibrosis and can partly explain the efficacy of these drugs in cases of heart failure and hypertension (2, 4, 5, 11).

Prevention and effective treatment of established cardiac disease according to guidelines for limiting the development of fibrosis is important (45).

---

## Conclusion

Modern biomarkers and diagnostic imaging have improved our understanding of myocardial fibrosis and its prognostic significance for several cardiac diseases. Improved methods for detection, an increased understanding of central molecular signalling pathways, and potential antifibrotic treatments are key areas of research (12). Assessment of myocardial fibrosis will probably gain a bigger place in the diagnosis, risk stratification and treatment of cardiac disease in the future.

---

*Thanks to Katrine Aronsen at the University Library in Trondheim for her contributions to the literature search, and research fellow Erik Andreas Rye Berg at the Norwegian University of Science and Technology for valuable input.*

## **Main points**

Myocardial fibrosis is defined as an increased quantity of collagenous scar tissue in the heart

Myocardial fibrosis may arise as a result of cardiac disease and/or extracardiac diseases

Myocardial fibrosis is associated with an unfavourable prognosis

Modern diagnostics facilitate the detection of myocardial fibrosis

---

## **LITERATURE**

1. Townsend N, Wilson L, Bhatnagar P et al. Cardiovascular disease in Europe: epidemiological update 2016. *Eur Heart J* 2016; 37: 3232 - 45. [PubMed][CrossRef]
2. Travers JG, Kamal FA, Robbins J et al. Cardiac fibrosis: the fibroblast awakens. *Circ Res* 2016; 118: 1021 - 40. [PubMed][CrossRef]
3. Piek A, de Boer RA, Silljé HH. The fibrosis-cell death axis in heart failure. *Heart Fail Rev* 2016; 21: 199 - 211. [PubMed][CrossRef]
4. Kong P, Christia P, Frangogiannis NG. The pathogenesis of cardiac fibrosis. *Cell Mol Life Sci* 2014; 71: 549 - 74. [PubMed][CrossRef]
5. Talman V, Ruskoaho H. Cardiac fibrosis in myocardial infarction-from repair and remodeling to regeneration. *Cell Tissue Res* 2016; 365: 563 - 81. [PubMed][CrossRef]
6. Dzeshka MS, Lip GY, Snezhitskiy V et al. Cardiac fibrosis in patients with atrial fibrillation: mechanisms and clinical implications. *J Am Coll Cardiol* 2015; 66: 943 - 59. [PubMed][CrossRef]
7. Barison A, Grigoratos C, Todiere G et al. Myocardial interstitial remodelling in non-ischaemic dilated cardiomyopathy: insights from cardiovascular magnetic resonance. *Heart Fail Rev* 2015; 20: 731 - 49. [PubMed][CrossRef]

8. Herum KM, Lunde IG, McCulloch AD et al. The soft- and hard-heartedness of cardiac fibroblasts: mechanotransduction signaling pathways in fibrosis of the heart. *J Clin Med* 2017; 6: E53. [PubMed][CrossRef]
9. López B, González A, Ravassa S et al. Circulating biomarkers of myocardial fibrosis: the need for a reappraisal. *J Am Coll Cardiol* 2015; 65: 2449 - 56. [PubMed][CrossRef]
10. Everett RJ, Stirrat CG, Semple SI et al. Assessment of myocardial fibrosis with T1 mapping MRI. *Clin Radiol* 2016; 71: 768 - 78. [PubMed][CrossRef]
11. Schelbert EB, Fonarow GC, Bonow RO et al. Therapeutic targets in heart failure: refocusing on the myocardial interstitium. *J Am Coll Cardiol* 2014; 63: 2188 - 98. [PubMed][CrossRef]
12. Heymans S, González A, Pizard A et al. Searching for new mechanisms of myocardial fibrosis with diagnostic and/or therapeutic potential. *Eur J Heart Fail* 2015; 17: 764 - 71. [PubMed][CrossRef]
13. Zeisberg M, Kalluri R. Cellular mechanisms of tissue fibrosis. 1. Common and organ-specific mechanisms associated with tissue fibrosis. *Am J Physiol Cell Physiol* 2013; 304: C216 - 25. [PubMed][CrossRef]
14. Chin CW, Vassiliou V, Jenkins WS et al. Markers of left ventricular decompensation in aortic stenosis. *Expert Rev Cardiovasc Ther* 2014; 12: 901 - 12. [PubMed][CrossRef]
15. Flett AS, Hayward MP, Ashworth MT et al. Equilibrium contrast cardiovascular magnetic resonance for the measurement of diffuse myocardial fibrosis: preliminary validation in humans. *Circulation* 2010; 122: 138 - 44. [PubMed][CrossRef]
16. Graham-Brown MP, Patel AS, Stensel DJ et al. Imaging of myocardial fibrosis in patients with end-stage renal disease: current limitations and future possibilities. *BioMed Res Int* 2017; 2017: 5453606. [PubMed][CrossRef]
17. Pattanayak P, Bleumke DA. Tissue characterization of the myocardium: state of the art characterization by magnetic resonance and computed tomography imaging. *Radiol Clin North Am* 2015; 53: 413 - 23. [PubMed][CrossRef]
18. Sado DM, Flett AS, Moon JC. Novel imaging techniques for diffuse myocardial fibrosis. *Future Cardiol* 2011; 7: 643 - 50. [PubMed][CrossRef]
19. Badiani S, van Zalen J, Treibel TA et al. Aortic stenosis, a left ventricular disease: insights from advanced imaging. *Curr Cardiol Rep* 2016; 18: 80. [PubMed][CrossRef]
20. Hundae A, McCullough PA. Cardiac and renal fibrosis in chronic cardiorenal syndromes. *Nephron Clin Pract* 2014; 127: 106 - 12. [PubMed][CrossRef]

21. Moon JC, Messroghli DR, Kellman P et al. Myocardial T1 mapping and extracellular volume quantification: a Society for Cardiovascular Magnetic Resonance (SCMR) and CMR Working Group of the European Society of Cardiology consensus statement. *J Cardiovasc Magn Reson* 2013; 15: 92. [PubMed][CrossRef]
22. Chin CWL, Everett RJ, Kwiecinski J et al. Myocardial fibrosis and cardiac decompensation in aortic stenosis. *JACC Cardiovasc Imaging* 2017; 10: 1320 - 33. [PubMed][CrossRef]
23. Quarto C, Dweck MR, Murigu T et al. Late gadolinium enhancement as a potential marker of increased perioperative risk in aortic valve replacement. *Interact Cardiovasc Thorac Surg* 2012; 15: 45 - 50. [PubMed][CrossRef]
24. Rudolph A, Abdel-Aty H, Bohl S et al. Noninvasive detection of fibrosis applying contrast-enhanced cardiac magnetic resonance in different forms of left ventricular hypertrophy relation to remodeling. *J Am Coll Cardiol* 2009; 53: 284 - 91. [PubMed][CrossRef]
25. de Meester de Ravenstein C, Bouzin C, Lazam S et al. Histological Validation of measurement of diffuse interstitial myocardial fibrosis by myocardial extravascular volume fraction from Modified Look-Locker imaging (MOLLI) T1 mapping at 3 T. *J Cardiovasc Magn Reson* 2015; 17: 48. [PubMed][CrossRef]
26. Bulluck H, Maestrini V, Rosmini S et al. Myocardial T1 mapping. *Circ J* 2015; 79: 487 - 94. [PubMed][CrossRef]
27. Chin CW, Pawade TA, Newby DE et al. Risk stratification in patients with aortic stenosis using novel imaging approaches. *Circ Cardiovasc Imaging* 2015; 8: e003421. [PubMed][CrossRef]
28. Dweck MR, Joshi S, Murigu T et al. Midwall fibrosis is an independent predictor of mortality in patients with aortic stenosis. *J Am Coll Cardiol* 2011; 58: 1271 - 9. [PubMed][CrossRef]
29. Milano AD, Faggian G, Dodonov M et al. Prognostic value of myocardial fibrosis in patients with severe aortic valve stenosis. *J Thorac Cardiovasc Surg* 2012; 144: 830 - 7. [PubMed][CrossRef]
30. Weidemann F, Herrmann S, Störk S et al. Impact of myocardial fibrosis in patients with symptomatic severe aortic stenosis. *Circulation* 2009; 120: 577 - 84. [PubMed][CrossRef]
31. Azevedo CF, Nigri M, Higuchi ML et al. Prognostic significance of myocardial fibrosis quantification by histopathology and magnetic resonance imaging in patients with severe aortic valve disease. *J Am Coll Cardiol* 2010; 56: 278 - 87. [PubMed][CrossRef]
32. Flett AS, Sado DM, Quarta G et al. Diffuse myocardial fibrosis in severe aortic stenosis: an equilibrium contrast cardiovascular magnetic resonance

study. *Eur Heart J Cardiovasc Imaging* 2012; 13: 819 - 26. [PubMed]  
[CrossRef]

33. Chin CW, Messika-Zeitoun D, Shah AS et al. A clinical risk score of myocardial fibrosis predicts adverse outcomes in aortic stenosis. *Eur Heart J* 2016; 37: 713 - 23. [PubMed][CrossRef]

34. Baumgartner H, Falk V, Bax JJ et al. 2017 ESC/EACTS Guidelines for the management of valvular heart disease. *Eur Heart J* 2017; 38: 2739 - 91. [PubMed][CrossRef]

35. Moreno MU, Eiros R, Gavira JJ et al. The hypertensive myocardium: from microscopic lesions to clinical complications and outcomes. *Med Clin North Am* 2017; 101: 43 - 52. [PubMed][CrossRef]

36. Treibel TA, Zemrak F, Sado DM et al. Extracellular volume quantification in isolated hypertension - changes at the detectable limits? *J Cardiovasc Magn Reson* 2015; 17: 74. [PubMed][CrossRef]

37. Almaas VM, Haugaa KH, Strøm EH et al. Increased amount of interstitial fibrosis predicts ventricular arrhythmias, and is associated with reduced myocardial septal function in patients with obstructive hypertrophic cardiomyopathy. *Europace* 2013; 15: 1319 - 27. [PubMed][CrossRef]

38. Doesch C, Sperb A, Sudarski S et al. Mitral annular plane systolic excursion is an easy tool for fibrosis detection by late gadolinium enhancement cardiovascular magnetic resonance imaging in patients with hypertrophic cardiomyopathy. *Arch Cardiovasc Dis* 2015; 108: 356 - 66. [PubMed][CrossRef]

39. Briasoulis A, Mallikethi-Reddy S, Palla M et al. Myocardial fibrosis on cardiac magnetic resonance and cardiac outcomes in hypertrophic cardiomyopathy: a meta-analysis. *Heart* 2015; 101: 1406 - 11. [PubMed]  
[CrossRef]

40. Hirsh BJ, Copeland-Halperin RS, Halperin JL. Fibrotic atrial cardiomyopathy, atrial fibrillation, and thromboembolism: mechanistic links and clinical inferences. *J Am Coll Cardiol* 2015; 65: 2239 - 51. [PubMed]  
[CrossRef]

41. Akoum N, Marrouche N. Assessment and impact of cardiac fibrosis on atrial fibrillation. *Curr Cardiol Rep* 2014; 16: 518. [PubMed][CrossRef]

42. Huynh K, Bernardo BC, McMullen JR et al. Diabetic cardiomyopathy: mechanisms and new treatment strategies targeting antioxidant signaling pathways. *Pharmacol Ther* 2014; 142: 375 - 415. [PubMed][CrossRef]

43. Waterhouse DF, Ismail TF, Prasad SK et al. Imaging focal and interstitial fibrosis with cardiovascular magnetic resonance in athletes with left ventricular hypertrophy: implications for sporting participation. *Br J Sports Med* 2012; 46 (suppl 1): i69 - 77. [PubMed][CrossRef]

44. Calvier L, Miana M, Reboul P et al. Galectin-3 mediates aldosterone-induced vascular fibrosis. *Arterioscler Thromb Vasc Biol* 2013; 33: 67 - 75. [PubMed][CrossRef]

45. Broberg CS, Burchill LJ. Myocardial factor revisited: The importance of myocardial fibrosis in adults with congenital heart disease. *Int J Cardiol* 2015; 189: 204 - 10. [PubMed][CrossRef]

---

Publisert: 12 October 2018. Tidsskr Nor Legeforen. DOI: 10.4045/tidsskr.17.1027

Received 20.11.2017, first revision submitted 19.3.2018, accepted 5.6.2018.

© Tidsskrift for Den norske legeforening 2026. Downloaded from tidsskriftet.no 2 July 2026.