
Stress echocardiography with semi-supine bicycle

REVIEW ARTICLE

HELGE SKULSTAD

Helge Skulstad (born 1965) is an MD, PhD, and Specialist in Internal Medicine and Cardiology. He is Senior Consultant at the Department of Cardiology, Oslo University Hospital Rikshospitalet, with echocardiography as an area of special interest.

The author has completed the ICMJE form and declares no conflicts of interest.

Email: helsku@ous-hf.no

Section of Cardiac Ultrasound

Department of Cardiology

Oslo University Hospital Rikshospitalet

SVEND AAKHUS

Svend Aakhus (born 1958) is an MD, PhD, and Specialist in Internal Medicine and Cardiology. He is Senior Consultant at the Department of Cardiology, Oslo University Hospital Rikshospitalet and Professor II at the Norwegian University of Science and Technology.

The author has completed the ICMJE form and declares no conflicts of interest.

Section of Cardiac Ultrasound

Department of Cardiology

Oslo University Hospital Rikshospitalet

Background:

Stress-related symptoms are often the reason that patients with cardiac disease are referred for echocardiographic assessment. We present a method for echocardiographic assessment with concurrent physiological stress where the patient is tested on a bicycle bench in a semi-supine position.

Material and method:

The paper is based on a literature search of PubMed and own experience of the method.

Results:

Ergometric stress echocardiography can be used for a number of cardiac conditions where an assessment of cardiac and haemodynamic response to physiological stress is wanted. Evaluation and follow-up of patients with hypertrophic cardiomyopathy, coarctation/recoarctation, mitral and aortic valve disorders have hitherto been the most important groups. The method can also provide important information about pulmonary hypertension and congenital heart defects.

Interpretation:

Ergometric stress echocardiography is a non-invasive method with little risk. It is a test that is relatively simple to conduct, and an important supplement to invasive methods.

Stress-related symptoms are often the reason why patients with cardiac disease are referred for specialist assessment. For regular echocardiography, the patient lies tilted to one side and is examined at rest. During rest, the haemodynamic state may be different from the situation when the patient experiences symptoms, and haemodynamic consequences of a heart disorder can be misjudged.

Stress echocardiography is a common designation for several methods. Drug-based stress echocardiography is often used in connection with examination for coronary disease, but is not described in further detail here. Echocardiography can also be undertaken prior to or immediately after exertion, such as knee-bending or cycling. To be able to monitor dynamic changes in the heart function and haemodynamics, a bicycle bench has been developed, on which the patient is placed in a semi-supine, tilted position, allowing for echocardiography to be undertaken simultaneously with the stress (ergonomic stress echocardiography) (Figure 1).

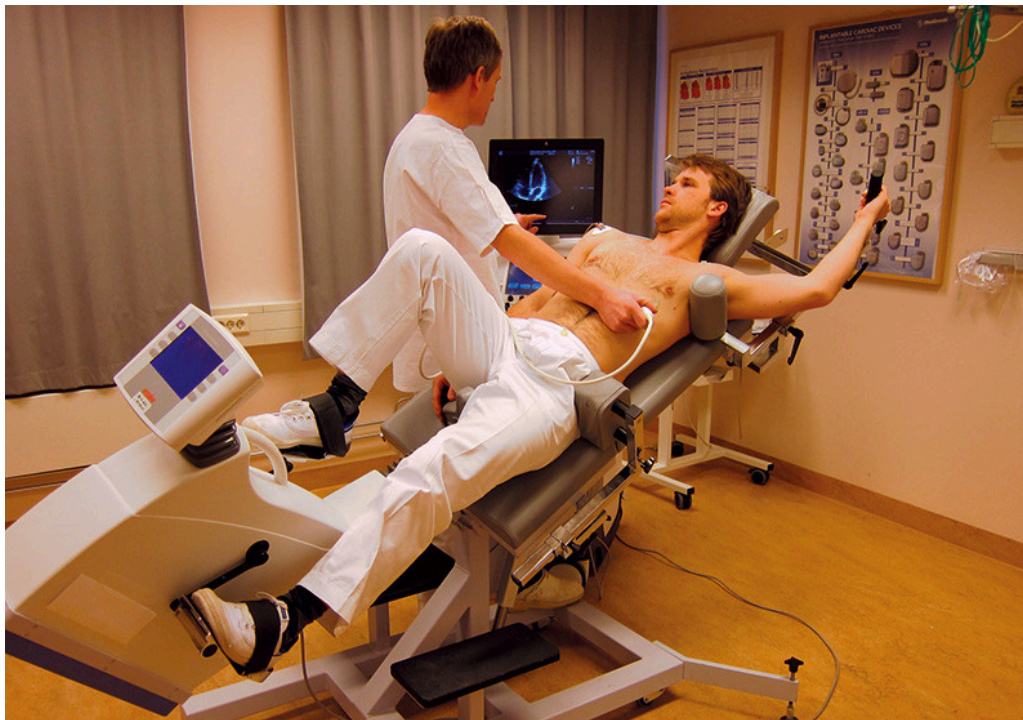

Figure 1: Illustration photo. A model on a supine bicycle in a semi-sitting, tilted position. This allows for simultaneous echocardiography with increasing stress. 12-lead ECG and the cuff for measuring blood pressure have not been attached, but are part of the examination protocol. Photo: Private.

Loads generally start at 20 W and are increased by 20 W every two minutes. Echo recordings are made at each level, as well as registration of heart rate, blood pressure and ECG. Most patients find that being tested on a bicycle bench is more strenuous than upright cycling, but it is attempted to achieve a stress resulting in a heart rate equal to 85 % of the age-adjusted maximum (220 minus age in years). During the test, the patients must be in a stable phase. The test is interrupted in case of chest pain, hypotension or arrhythmia.

The method is used on a daily basis in our hospital and a few other cardiological centres around the country. In this review article we wish to present relevant literature and provide examples of the clinical advantages achieved by ergometric stress echocardiography. In doing so, we hope to lay the foundation for more widespread use of this method in cardiological examinations.

Material and method

This review article is based on a search of literature in English in PubMed. The search was completed on 30 September 2011. The use of heterogeneous terminology complicated the literature search. We used «exercise, stress- or ergometric echocardiography», occasionally in combination with «bicycle», «supine», «semi-supine» or «treadmill».

We have as far as possible selected articles with original patient data. We did not find any randomised or controlled studies on the advantages of ergometric stress echocardiography in various patient groups.

Hypertrophic cardiomyopathy

Patients suffering from hypertrophic cardiomyopathy (HCM) often have dyspnoea and reduced capacity to work as their main symptoms. These are not very specific, and may be caused by systolic as well as diastolic dysfunction. In addition, this condition may occur both with and without any obstruction of the left ventricle outflow tract. Ergometric stress echocardiography is well suited for an examination of this condition. It has been shown that more than one-third of all patients with hypertrophic cardiomyopathy without any obstruction of outflow at rest may have a significant obstruction under stress [\(1\)](#). The obstruction increases the pressure drop in the left outflow tract, and it is assumed that a maximum pressure drop of > 30 mmHg and/or a stress-induced pressure drop of > 50 mmHg are of clinical significance. These values are used as a threshold for treatment with alcohol ablation or myectomy [\(2\)](#).

The pressure drop is calculated from bloodstream velocities measured by continuous Doppler from the apex of the heart by the simplified Bernoulli equation $\Delta P = 4v^2$ (where ΔP is the pressure drop measured in mmHg and v is the maximum blood-flow velocity measured in m/s) [\(3\)](#).

The obstruction of the outflow tract may cause the anterior leaflet of the mitral valve to be drawn forward during the systole and causes the so-called SAM (systolic anterior movement) phenomenon. This could result in an obstruction of the outflow tract, and a significant mitral insufficiency may occur. The blood flow from this mitral insufficiency may be located close to the blood flow in the outflow tract, so that distinguishing between them may be difficult. Often, parts of both velocity signals are included in the same registration. However, they can be distinguished by the fact that the blood flow in the mitral insufficiency starts earlier than the blood flow through the outflow tract, and because the obstruction produces a late-systolic, powerful acceleration of the blood-flow velocity, with a characteristic, knife-shaped signal (Figure 2).

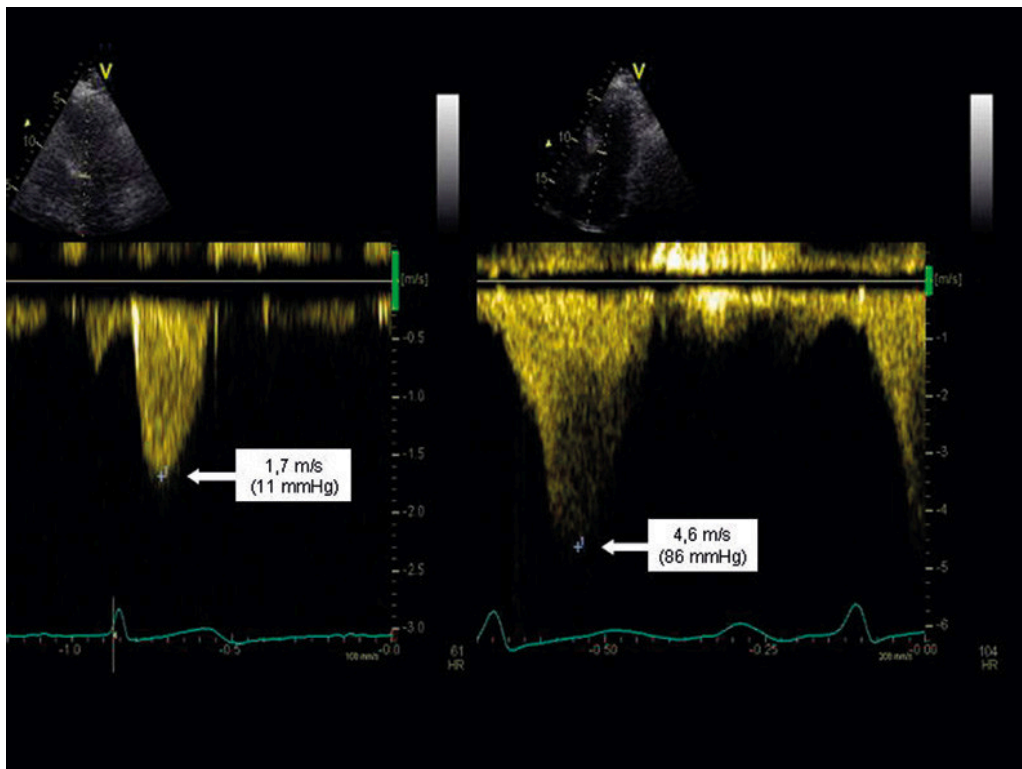


Figure 2. A patient with hypertrophic obstructive cardiomyopathy. Echocardiography with continuous Doppler registration of the outflow from the left ventricle. Recording at rest (left) and during exercise with a supine bicycle (80 W) (right). The two images have different scales for time and velocity. The figure shows the maximum blood-flow velocity and estimated pressure drop in the outflow from the left ventricle (the pressure drop is equal to the square of the velocity multiplied by 4). The estimated pressure drop increased from 11 mmHg at rest to 86 mmHg during physical exercise, which is consistent with a stress-induced increase in the outflow obstruction.

It is also important to note that outflow obstruction may occur in patients with healthy hearts during dobutamine stress echocardiography, but this procedure is mainly used in connection with coronary disease. It is not suitable for assessment of an obstruction of the blood flow in the outflow tract. In the case of a suspected obstruction, ergometric and not drug-based stress echocardiography should be used (2, 4).

Ergometric stress echocardiography can also indicate a latent failure of the left ventricle in patients with hypertrophic cardiomyopathy. A study discovered latent failure in 44 % of patients with hypertrophic cardiomyopathy without obstruction at rest and with no coronary disease (5). It has also been reported that the method can be used to distinguish between hypertrophic cardiomyopathy and training-induced hypertrophy («athlete's heart») – those who suffer from the latter develop no obstruction of the tract and have a hyperdynamic response during stress (6).

Mitral valve disease

The mitral valve has a complicated structure and function. Its function is determined by a dynamic interplay between the valve leaflet, the papillary muscles, the chordae, the mitral ring and the ventricular function. In addition,

the filling ratio (preload) and the resistance to outflow from the heart in the systole (afterload) may have an effect on the function of the valve. Considerable changes in the function may therefore occur during stress (7, 8).

Ergometric stress testing may be useful in case of mitral stenosis as well as mitral insufficiency. It is particularly useful when there is a discrepancy between the symptoms, the degree of valve dysfunction and pressure estimates (9, 10).

Mitral stenosis

One study has reported that patients who experience an increased drop in the mean pressure above the mitral valve to > 15 mmHg and/or a doubling of the pressure drop during physical exercise obtain a significant improvement of their symptoms after balloon dilatation of the mitral stenosis (11). Another study found that a stress-induced mean pressure drop > 15 mmHg indicated a valve area $< 1\text{cm}^2$ with a sensitivity of 84 % and a specificity of 76 % (12). On the basis of these findings, a drop in the mean pressure of > 15 mmHg can be recommended as a threshold for intervention (12, 13).

Patients with mitral stenosis may also have an elevated pressure in the pulmonary circulatory system. Correction of the stenosis is recommended at a systolic pulmonary artery pressure > 50 mmHg at rest, even with no visible symptoms (14). It has been shown that the pulmonary artery pressure increases during physical exercise in these patients, although the importance of this has not been identified (15). In general, a systolic pulmonary artery pressure of > 50 mmHg under stress is considered pathological (Figure 3).

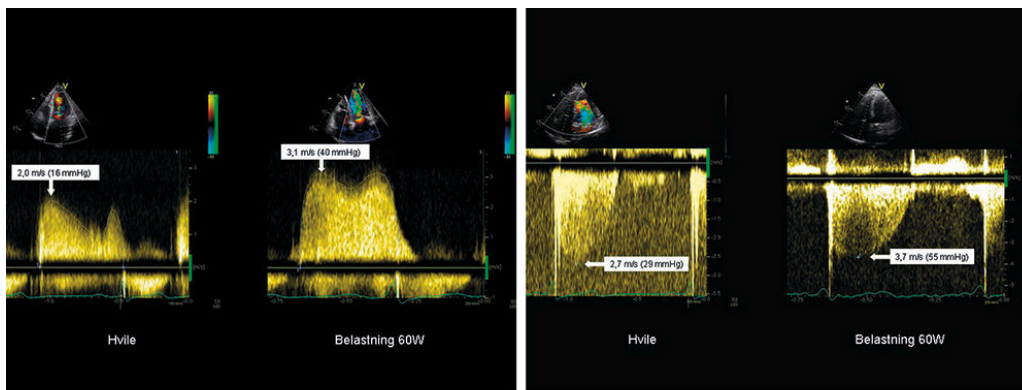


Figure 3: A young patient with dyspnoea during exercise. Doppler registrations from a) the mitral valve and b) the tricuspid valve at rest and during maximum exercise (60 W), respectively. Peak velocity and estimated pressure drop is provided. In addition, the mean velocity can be estimated by integrating the velocity curve, and a mean pressure drop can be estimated correspondingly (not shown in the figure). At rest, we see a moderate pressure drop above the mitral valve, with a peak value of 16 mmHg and an average value of 9 mmHg. b) The estimated pressure drop between the right ventricle and the atrium indicates a normal pressure in the pulmonary artery at rest. Under maximum stress, there is an increase in the pressure drop from 29 mmHg to 55 mmHg, which indicates a considerable increase in the pressure in the pulmonary artery. The examination shows a significant mitral stenosis, which became particularly manifest under stress.

Mitral insufficiency

Mitral insufficiency is the most dynamic of all valve disorders, and is the type of valve failure on which physical exercise has the highest impact (16). Mitral insufficiency may have an ischaemic or non-ischaemic aetiology, and this may be crucial for the prognosis and the choice of intervention. In addition, several factors, such as myocardial and papillary muscle function, the loading condition and coronary perfusion may have an impact on the function and dysfunction of the mitral valve. These factors change during physical exercise, and ergometric stress echocardiography is therefore a useful diagnostic supplement.

It has been shown that an increase of mitral insufficiency during physical exercise is a negative prognostic factor in patients with ischaemic mitral insufficiency and a simultaneously reduced function of the left ventricle, even though the insufficiency may be small or medium at rest (16, 17). In these patients, the degree of worsening during exercise is not related to the degree of insufficiency at rest, but to a local remodelling of the ventricle and a deformity of the mitral valve (18). The underlying mechanism appears to be that the pull from the papillary muscles on each valve leaflet increases during stress. A stress-induced imbalance in these forces may therefore result in considerable valve dysfunction (8).

Even patients with major mitral insufficiency may have few symptoms. Deciding when these patients ought to be operated on may thus be difficult. The timing may also to some extent depend on the surgical technique that can be used (mitral plastic surgery versus valve implantation). Few studies have focused on this issue. In a study of near-asymptomatic patients who all suffered from moderate or severe mitral insufficiency, echocardiography with treadmill stress was undertaken (19). It was demonstrated that if a contractile reserve in the left ventricle myocardium is present, i.e. the ventricle function improves during stress, the prognosis is better than when no such reserve is present. The findings indicate that ergometric echocardiography can be used to determine who should undergo surgery, especially by following the patient over time through repeated examinations.

An increase in the pulmonary artery pressure during exercise also indicates that the mitral insufficiency is of clinical significance. It has recently been shown that in asymptomatic patients with mitral insufficiency, an increase in the systolic pulmonary artery pressure to > 56 mmHg during stress is an independent predictor of the development of symptoms over the subsequent two years (20). This corroborates previous recommendations by the American Heart Association, stating that an increase in pulmonary artery pressure to > 60 mm Hg during physical stress in patients with asymptomatic severe mitral insufficiency could be an indication for surgery (10). As noted, the treatment strategy should not be based on this single criterion alone, but should be assessed in conjunction with other findings in the individual patient.

Follow-up after mitral-valve surgery and other interventions in the mitral valve

Some patients may have lasting symptoms after implantation of a mitral valve. This could be because the valve is too small in relation to the volume of blood that needs to pass through it (mismatch). Wherever this occurs, ergometric stress echocardiography can be used to assess the relationship between the valve area and the function of the valve [\(15\)](#).

Residual insufficiency and new stenosis are both possible complications of mitral plastic surgery. In case of such complications, the method can be used and the findings can be interpreted similarly to other insufficiency or stenosis [\(21\)](#).

Disease of the aortic valve

The aortic valve has a simpler structure than the mitral valve, and its function is only slightly influenced by physical stress. However, pathological valves can have an impact on the function of the left ventricle, and information on how this function changes during stress could be of significance for assessment of therapeutic interventions.

Aortic stenosis

Some patients with severe aortic stenosis have few or no symptoms, and making a clinical assessment of when they should undergo surgery may be difficult. Two studies of patients with severe aortic stenosis indicate that falling ejection fractions during ergometric stress echocardiography is a negative prognostic sign [\(22\)](#). Those who develop symptoms or pathological responses during such stress testing may have an increased risk of cardiac events [\(23\)](#). Furthermore, an increase in the fall in the pressure of > 18 mmHg has proven to be a negative prognostic sign. Both studies concluded that ergometric stress echocardiography could be useful in the clinical decision-making process.

Aortic insufficiency

A reduced contractile reserve (reduction in the ejection fraction of the left ventricle or increased end-systolic volume) during or immediately after stress is associated with an increased occurrence of left ventricular dysfunction over time [\(24, 25\)](#). Ergometric stress echocardiography may therefore be relevant with regard to determining the time of surgery for asymptomatic patients with severe aortic insufficiency.

Follow-up after aortic valve surgery

Wiseth and collaborators have found that there is a linear relationship between the maximum pressure drop over the valve at rest and the pressure drop during exercise in patients with small mechanical aortic valves [\(26\)](#). On the other hand, it was observed that symptoms occur most frequently in patients with a small left ventricle and less frequently among those who have the greatest pressure drop above the valve. It was therefore concluded that factors other than the pressure drop were decisive for cardiac symptoms after the implantation of a mechanical aortic valve.

Another study showed that the a similar increase in the pressure drop is achieved above a mechanical aortic valve during both drug-based and physiological testing (27), but the clinical consequences of a stress-induced increase in the pressure drop are uncertain. As yet, we have little knowledge to form a conclusion as to the benefits of ergometric stress echocardiography with regard to detect valvular mismatch after implantation of an aortic valve.

Pulmonary hypertension

Normally, pulmonary artery pressure increases during stress. This is because of increased volume per minute, and is not due to vascular resistance (28, 29). What should be considered normal increase in pressure remains undetermined, and a systolic pulmonary artery pressure of 35 – 50 mmHg has been proposed as an upper limit of the normal value (30, 31).

It is also worth noting that physically fit athletes with normal heart function represent a sub-group of the normal population. They can develop a stress-induced systolic pulmonary artery pressure > 60 mmHg, which in other contexts is considered a pathological value (32).

Studies on exercise-induced pulmonary hypertension in patients with connective-tissue disorders have been undertaken. Taking the described limitations into account, the method appears to be able to detect an underlying or mild pulmonary hypertension (30). Whether this may provide any clinical advantages remains to be seen, however.

Coarctation and re-coarctation of the aorta

Coarctation of the aorta is one of the most common congenital heart defects. If it is left untreated, the life expectancy is approximately half that of the normal population (33). Patients with coarctation usually undergo surgery as children, but late-onset complications may occur in the form of aneurysms, re-coarctation and hypertension (34, 35). Those who have undergone surgery should be re-examined every second year as a minimum (36).

Re-coarctation can be estimated with echocardiography, and a pressure drop of > 20 – 30 mmHg at rest is suggested as a threshold for intervention (36). In case of a lower pressure drop, ergometric stress echocardiography can be used to determine the significance of the residual stenosis during physical exercise. In this context, 50 mmHg is used as a flexible limit. However, it is equally important to assess whether there is a «diastolic tail» (Figure 4) (37), which may indicate a haemodynamic significance of the (re-)coarctation.

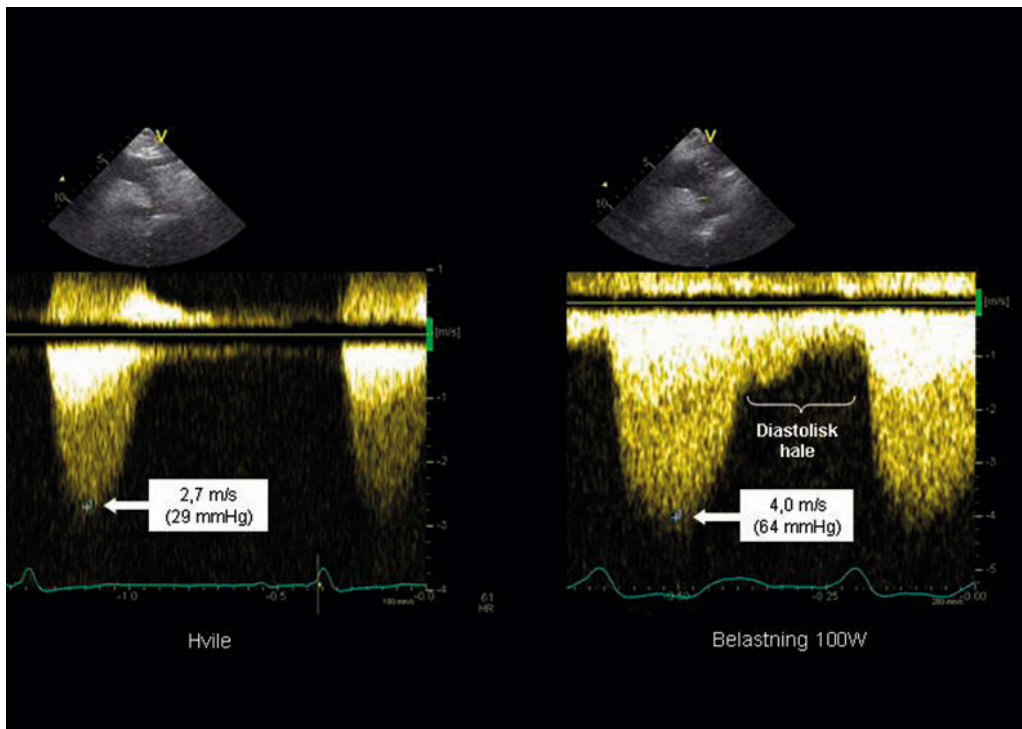


Figure 4: Echo recordings from a patient referred for a possible reocartation after a previous operation for coarctation. The images demonstrate continuous Doppler recordings from the descending part of the aortic arc. On the left, we see recordings at rest with a peak velocity of 2.7 m/s and an estimated pressure drop of 29 mmHg, on the right we see recordings made during exercise at 100 W, with a velocity increasing to 4.0 m/s, resulting in a pressure drop of 64 mmHg (note the different scales for blood-flow velocity in the two images). Note also the addition of a distinct «diastolic tail».

Other congenital heart defects

The method can also be used to examine patients with other types of congenital heart defects – for example septum defects, Fallot’s tetralogy, transposition of the large arteries and congenital defects of the heart valves (38). In case of such structural heart defects, detection of changes to ventricular function, lack of a functional reserve, a stress-induced increase in the pressure drop above a stenosis or an increase in the pulmonary circulatory system may have diagnostic and therapeutic significance.

Summing up

Ergometric stress echocardiography with a supine bicycle can be used for a number of cardiac conditions where an assessment of the haemodynamic response to physical exercise is desired. The method provides important diagnostic information and improved understanding of pathophysiological mechanisms. It is best established as a suitable method in patients with hypertrophic cardiomyopathy, mitral stenosis and coarctation/reoarctation.

The method can also provide supplementary information in case of other conditions, especially conditions where an increase in the pressure drop above the valves during physical exercise is of interest.

Tabell

Main message
<ul style="list-style-type: none">• Ergometric stress echocardiography should be considered for all patients suffering from a structural heart disorder, especially if there is a discrepancy between symptoms and findings at rest.• The method is non-invasive and entails minimum risk, it is low-cost and easily available.• Stress echocardiography is a supplement as well as an alternative to invasive methods.

LITERATURE

1. Marwick TH, Nakatani S, Haluska B et al. Provocation of latent left ventricular outflow tract gradients with amyl nitrite and exercise in hypertrophic cardiomyopathy. *Am J Cardiol* 1995; 75: 805 – 9. [PubMed] [CrossRef]
2. Maron BJ, McKenna WJ, Danielson GK et al. American College of Cardiology/European Society of Cardiology Clinical Expert Consensus Document on Hypertrophic Cardiomyopathy. A report of the American College of Cardiology Foundation Task Force on Clinical Expert Consensus Documents and the European Society of Cardiology Committee for Practice Guidelines. *Eur Heart J* 2003; 24: 1965 – 91. [PubMed] [CrossRef]
3. Feigenbaum H. *Echocardiography*. Philadelphia, PA: Lea & Febiger, 1986.
4. Pellikka PA, Oh JK, Bailey KR et al. Dynamic intraventricular obstruction during dobutamine stress echocardiography. A new observation. *Circulation* 1992; 86: 1429 – 32. [PubMed] [CrossRef]
5. Okeie K, Shimizu M, Yoshio H et al. Left ventricular systolic dysfunction during exercise and dobutamine stress in patients with hypertrophic cardiomyopathy. *J Am Coll Cardiol* 2000; 36: 856 – 63. [PubMed] [CrossRef]
6. Abernethy WB, Choo JK, Hutter AM jr. Echocardiographic characteristics of professional football players. *J Am Coll Cardiol* 2003; 41: 280 – 4. [PubMed] [CrossRef]
7. Voelker W, Berner A, Regele B et al. Effect of exercise on valvular resistance in patients with mitral stenosis. *J Am Coll Cardiol* 1993; 22: 777 – 82. [PubMed] [CrossRef]
8. Levine RA, Hung J. Ischemic mitral regurgitation, the dynamic lesion: clues to the cure. *J Am Coll Cardiol* 2003; 42: 1929 – 32. [PubMed]

[CrossRef]

9. Wu WC, Aziz GF, Sadaniantz A. The use of stress echocardiography in the assessment of mitral valvular disease. *Echocardiography* 2004; 21: 451 – 8. [PubMed] [CrossRef]
10. Bonow RO, Carabello BA, Chatterjee K et al. ACC/AHA 2006 guidelines for the management of patients with valvular heart disease: a report of the American College of Cardiology/American Heart Association Task Force on Practice Guidelines (writing Committee to Revise the 1998 guidelines for the management of patients with valvular heart disease) developed in collaboration with the Society of Cardiovascular Anesthesiologists endorsed by the Society for Cardiovascular Angiography and Interventions and the Society of Thoracic Surgeons. *J Am Coll Cardiol* 2006; 48: e1 – 148. [PubMed] [CrossRef]
11. Aviles RJ, Nishimura RA, Pellikka PA et al. Utility of stress Doppler echocardiography in patients undergoing percutaneous mitral balloon valvotomy. *J Am Soc Echocardiogr* 2001; 14: 676 – 81. [PubMed] [CrossRef]
12. Cheriex EC, Pieters FA, Janssen JH et al. Value of exercise Doppler-echocardiography in patients with mitral stenosis. *Int J Cardiol* 1994; 45: 219 – 26. [PubMed] [CrossRef]
13. Pellikka PA, Nagueh SF, Elhendy AA et al. American Society of Echocardiography recommendations for performance, interpretation, and application of stress echocardiography. *J Am Soc Echocardiogr* 2007; 20: 1021 – 41. [PubMed] [CrossRef]
14. Baumgartner H, Bonhoeffer P, De Groot NM et al. ESC Guidelines for the management of grown-up congenital heart disease (new version 2010). *Eur Heart J* 2010; 31: 2915 – 57. [PubMed] [CrossRef]
15. Leavitt JI, Coats MH, Falk RH. Effects of exercise on transmitral gradient and pulmonary artery pressure in patients with mitral stenosis or a prosthetic mitral valve: a Doppler echocardiographic study. *J Am Coll Cardiol* 1991; 17: 1520 – 6. [PubMed] [CrossRef]
16. Lancellotti P, Troisfontaines P, Toussaint AC et al. Prognostic importance of exercise-induced changes in mitral regurgitation in patients with chronic ischemic left ventricular dysfunction. *Circulation* 2003; 108: 1713 – 7. [PubMed] [CrossRef]
17. Peteiro J, Bendayan I, Mariñas J et al. Prognostic value of mitral regurgitation assessment during exercise echocardiography in patients with left ventricular dysfunction: a follow-up study of 1.7 +/- 1.5 years. *Eur J Echocardiogr* 2008; 9: 18 – 25. [PubMed]
18. Lancellotti P, Lebrun F, Piérard LA. Determinants of exercise-induced changes in mitral regurgitation in patients with coronary artery disease and

- left ventricular dysfunction. *J Am Coll Cardiol* 2003; 42: 1921 – 8. [PubMed] [CrossRef]
19. Lee R, Haluska B, Leung DY et al. Functional and prognostic implications of left ventricular contractile reserve in patients with asymptomatic severe mitral regurgitation. *Heart* 2005; 91: 1407 – 12. [PubMed] [CrossRef]
 20. Magne J, Lancellotti P, Piérard LA. Exercise pulmonary hypertension in asymptomatic degenerative mitral regurgitation. *Circulation* 2010; 122: 33 – 41. [PubMed] [CrossRef]
 21. Agricola E, Maisano F, Oppizzi M et al. Mitral valve reserve in double-orifice technique: an exercise echocardiographic study. *J Heart Valve Dis* 2002; 11: 637 – 43. [PubMed]
 22. Maréchaux S, Ennezat PV, LeJemtel TH et al. Left ventricular response to exercise in aortic stenosis: an exercise echocardiographic study. *Echocardiography* 2007; 24: 955 – 9. [PubMed] [CrossRef]
 23. Lancellotti P, Lebois F, Simon M et al. Prognostic importance of quantitative exercise Doppler echocardiography in asymptomatic valvular aortic stenosis. *Circulation* 2005; 112 (suppl): I377 – 82. [PubMed]
 24. Wahi S, Haluska B, Pasquet A et al. Exercise echocardiography predicts development of left ventricular dysfunction in medically and surgically treated patients with asymptomatic severe aortic regurgitation. *Heart* 2000; 84: 606 – 14. [PubMed] [CrossRef]
 25. Gabriel RS, Kerr AJ, Sharma V et al. B-type natriuretic peptide and left ventricular dysfunction on exercise echocardiography in patients with chronic aortic regurgitation. *Heart* 2008; 94: 897 – 902. [PubMed] [CrossRef]
 26. Wiseth R, Levang OW, Tangen G et al. Exercise hemodynamics in small (< or = 21 mm) aortic valve prostheses assessed by Doppler echocardiography. *Am Heart J* 1993; 125: 138 – 46. [PubMed] [CrossRef]
 27. Kadir I, Walsh C, Wilde P et al. Comparison of exercise and dobutamine echocardiography in the haemodynamic assessment of small size mechanical aortic valve prostheses. *Eur J Cardiothorac Surg* 2002; 21: 692 – 7. [PubMed] [CrossRef]
 28. Bossone E, Rubenfire M, Bach DS et al. Range of tricuspid regurgitation velocity at rest and during exercise in normal adult men: implications for the diagnosis of pulmonary hypertension. *J Am Coll Cardiol* 1999; 33: 1662 – 6. [PubMed] [CrossRef]
 29. Wagner PD, Gale GE, Moon RE et al. Pulmonary gas exchange in humans exercising at sea level and simulated altitude. *J Appl Physiol* 1986; 61: 260 – 70. [PubMed]
 30. Collins N, Bastian B, Quiqueree L et al. Abnormal pulmonary vascular responses in patients registered with a systemic autoimmunity database:

Pulmonary Hypertension Assessment and Screening Evaluation using stress echocardiography (PHASE-I). *Eur J Echocardiogr* 2006; 7: 439 – 46.

[PubMed] [CrossRef]

31. Callejas-Rubio JL, Moreno-Escobar E, Martín de la Fuente P et al. Pulmonary hypertension and exercise echocardiography. *Eur J Echocardiogr* 2006; 7: 261 – 2, author reply 263. [PubMed] [CrossRef]

32. Möller T, Peersen K, Pettersen E et al. Non-invasive measurement of the response of right ventricular pressure to exercise, and its relation to aerobic capacity. *Cardiol Young* 2009; 19: 465 – 73. [PubMed] [CrossRef]

33. Campbell M. Natural history of coarctation of the aorta. *Br Heart J* 1970; 32: 633 – 40. [PubMed] [CrossRef]

34. Cohen M, Fuster V, Steele PM et al. Coarctation of the aorta. Long-term follow-up and prediction of outcome after surgical correction. *Circulation* 1989; 80: 840 – 5. [PubMed] [CrossRef]

35. Swan L, Wilson N, Houston AB et al. The long-term management of the patient with an aortic coarctation repair. *Eur Heart J* 1998; 19: 382 – 6. [PubMed] [CrossRef]

36. Deanfield J, Thaulow E, Warnes C et al. Management of grown up congenital heart disease. *Eur Heart J* 2003; 24: 1035 – 84. [PubMed] [CrossRef]

37. Guenthard J, Wyler F. Doppler echocardiography during exercise to predict residual narrowing of the aorta after coarctation resection. *Pediatr Cardiol* 1996; 17: 370 – 4. [PubMed] [CrossRef]

38. Sadaniantz A, Katz A, Wu WC. Miscellaneous use of exercise echocardiography in patients with chronic pulmonary disease or congenital heart defect. *Echocardiography* 2004; 21: 477 – 84. [PubMed] [CrossRef]

Publisert: 16. October 2012. Tidsskr Nor Legeforen. DOI: 10.4045/tidsskr.11.1538

Received 9 January 2012, first revision submitted 27 March 2012, approved 9 August 2012.

Medical editor: Merete Kile Holtermann.

© Tidsskrift for Den norske legeforening 2026. Downloaded from tidsskriftet.no 3 July 2026.