
An infant's failure to thrive ended in death

EDUCATIONAL CASE REPORT

PAAL H.H. LINDENSKOV

Paal H.H. Lindenskov, MD PhD (b. 1962) is a Specialist in Anaesthesiology and Paediatrics.

The author has completed the ICMJE form and declares no conflicts of interest.

* Current address:

Department of Anaesthesiology
Division of Emergencies and Critical Care
Oslo University Hospital Rikshospitalet
Email: uxlpa@ous-hf.no

ARILD RØNNESTAD

Arild Rønnestad, MD PhD (b. 1956) is a Specialist in Paediatrics.

The author has completed the ICMJE form and declares the following conflicts of interest: He has received fees for an expert medical opinion commissioned by the Norwegian System of Patient Injury Compensation.

Department of Neonatal Intensive Care
Women and Children's Division
Oslo University Hospital Rikshospitalet

HANS SKARI

Hans Skari, MD PhD (b. 1963) is a Specialist in General Surgery and Paediatric Surgery.

The author has completed the ICMJE form and declares no conflicts of interest.

Section for Paediatric Surgery
Department of Gastrointestinal and Paediatric Surgery
Division of Cancer Medicine, Surgery and Transplantation
Oslo University Hospital

A boy who had a minor lung puncture at birth died at the age of four weeks after slow weight gain, failure to thrive, vomiting and poor urinary flow.

The boy was born after 37 weeks gestation with a birth weight of 4 030 g, corresponding to the 75th percentile for weight at birth. During an ultrasound examination in Week 17 of the pregnancy the midwife had a suspicion that the urinary bladder was enlarged, but this was not confirmed at a hospital examination later in the pregnancy. After birth the boy was hospitalised for a short period of time in the local neonatal unit because of laboured respiration. A minor lung puncture was detected.

In the neonatal period the parents noted that the boy had slow weight gain and therefore contacted the primary healthcare services. The parents also observed that the boy had a poor urinary flow. When the patient was two weeks old, he was referred to hospital with an incarcerated inguinal hernia which was repaired after 2.5 hours.

The boy collapsed at home, at barely four weeks of age. This occurred after several days of failure to thrive, vomiting and lack of bowel movement, and consultation with the local public health clinic. Resuscitation was instituted within a few minutes by healthcare professionals who happened to be close at hand, with further assistance after 25 minutes by air ambulance personnel. After 45 minutes a slow heart rate of 90 bpm (120 – 160 bpm) was ascertained.

Postnatal collapse in the first weeks of life may be the result of a duct-dependent heart defect because pulmonary or systemic circulation depends on the ductus arteriosus. At the foetal stage this acts as a shunt between the pulmonary artery and the aorta, and will normally close in the first days after birth, but may be delayed by hypoxia, acidosis or serious infections. The closing of ductus arteriosus in neonates with duct-dependent heart defects will either reduce pulmonary circulation and result in hypoxaemia as in pulmonary atresia, or in the case of duct-dependent systemic circulation will lead to circulatory collapse as in hypoplastic left heart syndrome, aortic stenosis and arcus aortae anomalies. Circulatory collapse is measured as low blood pressure, low pulse amplitude with a loss of peripheral pulses, prolonged capillary refill time, reduced to diuresis failure and metabolic lactic acidosis.

Two other important causes of collapse in neonates are systemic bacterial infections, so-called «late onset sepsis», and congenital metabolic diseases. The latter manifest themselves after regression of the placenta's temporary metabolism for enzyme failure, and this results in energy failure and perhaps toxic metabolites.

On arrival at the hospital, the patient had hypothermia (31 °C), a weak femoral pulse and cold skin. Using a cuff, his blood pressure was non-measurable. The pupils were dilated and the abdomen considerably distended and taut. A reducible inguinal hernia was detected. The S-potassium level was high (tab 1).

Table 1

A selection of the patient's blood test results. Venous tests and reference values for neonates unless otherwise specified.

Blood tests	Patient	Reference value
CRP (mg/l)	156	< 4
Haemoglobin (g/dl)	8.4	9.0–14.0
Thrombocytes ($\cdot 10^9/l$)	15	150–600
Sodium (mmol/l)	125	136–146
Potassium (mmol/l)	10.2	3.4–5.3
Magnesium (mmol/l)	1.5	0.71–0.94

Blood tests	Patient	Reference value
Phosphate (mmol/l)	4.5	1.2–2.0
Albumin (g/l)	16.1	36–48
Carbamide (mmol/l)	54.4	3.2–8.1
Creatinine (µmol/l)	348	14–34
Lactate (mmol/l)	19	0.4–0.8
pH (arterial test)	6.47	7.35–7.45
Plasma renin activity (nmol/l/t)	28.6	0.5–1.5 ¹
Plasma aldosterone (pmol/l)	70 112	70–80 ¹
[i]		

[i] ¹ Indicative reference value for adults

Hyperkalemia-induced cardiac arrhythmia could explain the primary collapse and – until the potassium level had been normalised – episodic arrhythmias occurred with broader QRS complexes. It was noted that the patient, despite clinical signs of poor peripheral circulation and non-measurable blood pressure when a cuff was used, proved to have a blood pressure of 80/40 mm Hg when measured using a femoral arterial catheter. This reading is within the normal range, but is considered high in connection with a circulatory collapse.

The patient's dilated pupils on admission were explained by the adrenaline used during resuscitation. Alternatively, this could have been caused by compression of the parasympathetic pathway to the oculomotor nerve against the tentorium cerebelli. This can occur in connection with increased intracranial pressure caused by secondary oedema at hypoxic brain injury. However, this type of oedema develops in the course of days rather than hours following an hypoxic incident. Furthermore, the ultrasound examination of the cerebrum undertaken on admission showed no sign of increased intracerebral pressure and no intracerebral bleeding. The Doppler test established that the intracerebral circulation was normal.

Due to the distended abdomen, a bowel perforation was initially suspected, possibly secondary to a strangulated inguinal hernia with complications in the form of peritonitis and systemic inflammatory response. This could also result in a circulatory collapse and the development of prerenal kidney failure.

An abdominal ultrasound examination with Doppler showed normal intestinal peristalsis and a normal flow signal in the superior mesenteric artery; also, the intestines were found not to be dilated. An x-ray examination failed to establish free air in the abdominal cavity.

On admission, the boy had raised CRP, a low platelet count and coagulation tests consistent with disseminated intravascular coagulation (DIC) and systemic infection. The patient received a transfusion of blood platelets, erythrocytes and plasma. Pressor therapy in the form of vasopressin and high-dose noradrenaline infusion was initiated after PiCCO (pulse induced continuous cardiac output) readings showed a high heart minute volume combined with low peripheral resistance; this was interpreted as septic capillary dilation. Echocardiography showed slightly increased rates of flow from all ostia, consistent with hyperkinetic circulation.

A small cloudy urine sample was taken via a catheter (nutrition catheter Ch 6) which was introduced with difficulty. Chemical analysis of the urine showed pyuria and proteinuria, but the nitrite test was negative.

The majority of urinary tract pathogenic bacteria, except enterococci, yield a positive nitrite test result.

Overgrowth of enterococci was found in the catheter urine, blood and ascitic fluid. Treatment for urosepsis was initiated with high doses of cefotaxime, ampicillin and metronidazole. The ultrasound examination showed enlarged kidneys with increased echo signal intensity, thickening of the urinary bladder wall, as well as dilation of the renal pelvises and ureters.

Severe lactic acidosis was established, as well as hyponatraemia, hyperkalaemia, hypermagnesaemia, hyperphosphataemia, hypoalbuminaemia, a high carbamide concentration, a high creatine level and anaemia. In other words, clinically and biochemically the patient was in kidney failure and did not respond to diuretic medication. Consequently, peritoneal dialysis was initiated.

The patient had a fulminant bacterial sepsis accompanied by disseminated intravascular coagulation. The agent proved to be enterococci, which most probably spread from the urinary tract. Because the parents had never observed a normal urinary flow, and because the ultrasound examination of the urinary tract established bladder hypertrophy and bilaterally dilated collecting systems, there was reason to believe that there was an obstruction of the urinary tract in the form of congenital posterior urethral valves.

The blood test taken on admission showed increased plasma renin activity and aldosterone levels, consistent with so-called pseudohypoaldosteronism (PHA).

Residual urine following obstructions of the urinary tract may provide the water phase required for bacteria to grow. Furthermore, increased bladder pressure generated by outlet obstruction may cause vesicoureteral reflux accompanied by bacterial spread to the renal pelvises, development of interstitial nephritis and hematogenous spread (Figure 1). Increased intra-abdominal pressure at bladder evacuation could also explain the patient's inguinal hernia.

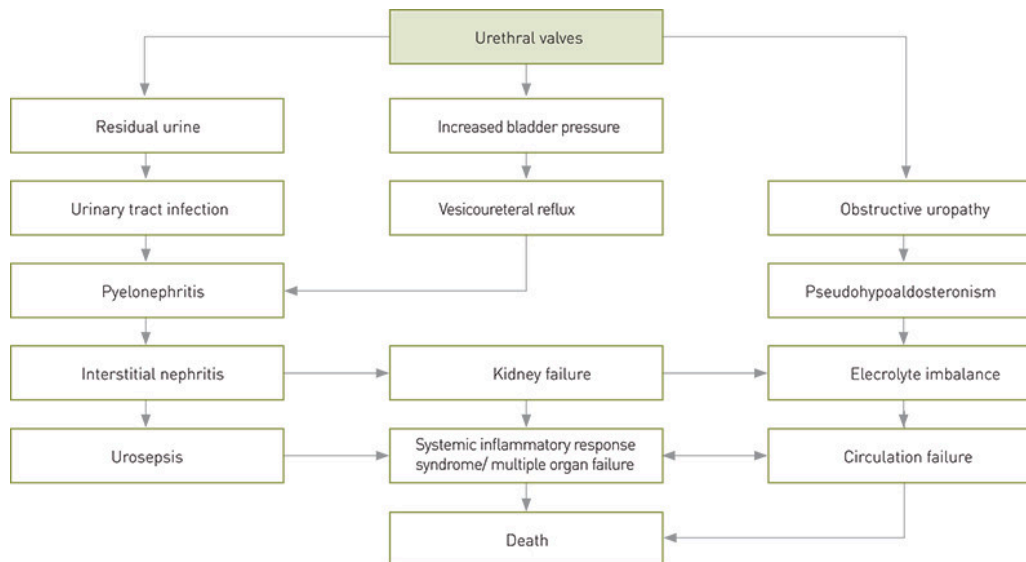


Figure 1 Possible consequences of urethral valves in infants. The figure is based on Paal H.H. Lindenskov's layout

Despite ongoing intensive care, the patient's condition worsened and he died three days after admission. The post mortem examination found urethral valves, extremely dilated ureters, renal pelvis dilation on both sides, a necrotic left kidney, pus in the right kidney pelvis and thickening of the urinary bladder wall.

Discussion

Due to urinary tract outlet obstruction in the form of urethral valves, the patient contracted a urinary tract infection which developed into a life-threatening systemic infection. Additionally, the endocrine condition pseudohypoaldosteronism (PHA) arose, which may explain some of the symptoms displayed before and during the dramatic septic event. Our assertion is that transient pseudohypoaldosteronism is a neglected condition in infants with obstructive uropathies. This is not a frequent condition in infants, but the consequences may be serious unless the diagnosis is established in time and treatment is directed at the underlying cause. The condition is normalised by surgical correction of the obstructive uropathy.

Pseudohypoaldosteronism may be familial but is normally transient, arising as a consequence of a urinary tract obstruction. Paradoxically, all forms of this condition display extremely high levels of plasma aldosterone. The mechanism is probably an ACTH-mediated compensatory synthesis of aldosterone caused by a reduced aldosterone response in the distal kidney tubules (Figure 2). Due to the salt loss, the children's weight gain is poor and they demonstrate a general failure to thrive. Hyperkalaemia is also found to varying degrees, as is metabolic acidosis, water loss and compromised peripheral circulation (fig 2) (1) – (5).

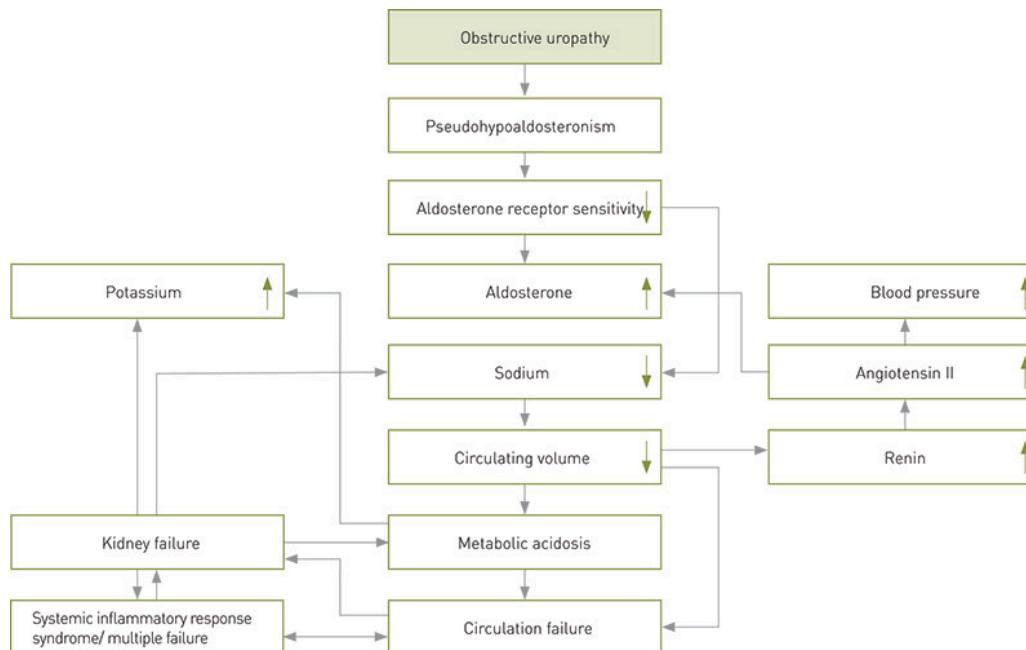


Figure 2 Pathophysiology in obstructive uropathy. The figure is based on Paal H.H. Lindenskov's layout

In 1958, Cheek & Perry described a familial form of pseudohypoaldosteronism in infancy as a salt-losing condition with normal kidney and adrenal gland functions, later known as PHA type I for which cyanosis is described as an initial symptom (2). Phenotypically, the condition displays either a renal or a generalised form of aldosterone resistance, the former with a mild clinical progression accompanied by light hyponatraemia, the latter with more complex symptoms involving aldosterone resistance in monocytes, lymphocytes, salivary glands, sudoriferous glands and kidney tubules (6, 7).

Like PHA type I, PHA type II is also familial; it is, however, rarer (8). PHA type II is differentiated from PHA type I by hypertension, low renin levels, and a hyperchloremic rather than a hypochloremic metabolic acidosis without salt loss (tab

2). For PHA type II, sodium restriction is therefore recommended, while PHA type I is treated with sodium supplements (Table 3).

Table 2

Indicative biochemical profiles for salt-losing syndromes in infants. The table is based on Paal H.H. Lindenskov's layout

	Salt		Potassium Chloride		Renin	Aldosterone	Metabolic
	Potassium (serum)	loss in urine	(serum)	(serum)	activity (plasma)	(serum)	acidosis
PHA I	↓	↑	↑	↓	↑↑	↑↑↑	++
PHA II	↓		↑	↑	↓	↑	
Transient PHA	↓	↑	↑	↓	↑↑	↑↑↑	++
Adrenogenital syndrome	↓	↑		↓		↓↓	+
Bartter syndrome	↓	↑	↓	↓	↑	↑	Alkalosis
Selective hypoaldosteronism	↓	↑	↑	↓	↑	↓	+
Pyelonephritis	↓				↑	↑	+
PHA = pseudohypoaldosteronism							

Table 3

Treatment profiles and failure to thrive insalt-losing syndromes in infants. The table is based on Paal H.H. Lindenskov's layout

	«Failure to thrive»	Effect of mineralocorticoids	Effect of glucocorticoids	Indication for surgery	Indication for salt supplement
PHA I	++	-	-	-	+
PHA II	+	-	-	-	Restriction
Sporadic PHA	++	-	-	+	+
Adrenogenital syndrome	++	++	++	-	+
Bartter syndrome	-	-	-	-	
Selective hypoaldosteronism	+	++	-	-	+
PHA = pseudohypoaldosteronism					

Our patient suffered from none of the familial forms, but rather the transient form first described by Rodríguez-Soriano et al. in 1983 (9). Four of six patients in their material were associated with obstructive uropathy. The obstructive uropathy may be caused by ureteropelvic junction stenosis, bilateral terminal ureteral stenosis, ectopic ureterocele, meatal stenosis and not least – urethral valves. In a wider sense, vesicoureteral reflux is also included among the obstructive uropathies because the condition causes increased pressure in the kidney pelvis (10, 11). Transient

pseudohypoaldosteronism has been described by many (4, 10) – (13); the condition manifests itself after the neonatal period with vague symptoms in the form of slow weight gain, signs of failure to thrive, and gradually also vomiting and dehydration. Failure to thrive and poor weight gain are also symptoms of congenital heart disease, congenital metabolic disease or less serious conditions such as poor breast feeding techniques and hypertrophic pyloric stenosis. One case report described the condition as hypertrophic pyloric stenosis, probably caused by a urinary tract infection (14). Undiagnosed, transient pseudohypoaldosteronism may progress into the fulminant form, presenting with salt-losing nephropathy accompanied by hyperkalaemia, hyponatraemia and normochloremic or hypochloremic metabolic acidosis (fig 2). The condition is diagnosed by extremely high plasma aldosterone levels and renin activity, both of which are reversible by correcting the obstructive uropathy (Figure 2). However, one instance of persistent pseudohypoaldosteronism is described, caused by unilateral kidney dysplasia following a vesicoureteral reflux (3).

Our patient had a pneumothorax at birth. The connection between spontaneous pneumothorax at birth and obstructive urinary tract anomaly is well known (15, 16). A possible cause may be pulmonary hypoplasia after varying degrees of oligohydramnios (17, 18). Spontaneous pneumothorax has also been described in connection with transient pseudohypoaldosteronism (19). We suggest that any spontaneous pneumothorax in fully gestated infants who have not been exposed to positive pressure ventilation should instigate an assessment for potential urinary tract anomalies, with or without pseudohypoaldosteronism.

Transient pseudohypoaldosteronism may occur even if there is no obstructive uropathy, as is the case with pyelonephritis (13). The biochemical changes described for pyelonephritis are similar to those described for a normocalcemic pseudohypoaldosteronism with sodium in the lower normal range at the initial stages of infection, and with persistent high levels of renin and aldosterone in patients with scarring established by DMSA scintigraphy (20). Some authors will therefore maintain that the infection is the cause of the pseudohypoaldosteronism, not the obstructive uropathy (21). Tables 2 and 3 show biochemical profiles and treatment profiles for various types of the condition as well as some relevant differential diagnoses.

We conclude that in infants, vague symptoms such as poor weight gain and failure to thrive may be caused by transient pseudohypoaldosteronism secondary to obstructive uropathy. Coupled with secondary infection spread from the urinary tract, the condition may contribute to the development of circulatory collapse. Helpful diagnostic tests include blood pressure measurements, measurements of electrolytes in blood and urine, ultrasound examination of the urinary tract and measurements of plasma renin activity and plasma aldosterone levels. However, in an infant it is of paramount importance to discover an obstructive uropathy in time.

The patient's parents have consented to the publication of this article.

LITERATURE

1. Buzi F, Bezante T, Brunori A et al. Pseudohypoaldosteronism: report of a case presenting as failure to thrive. *J Pediatr Endocrinol Metab* 1995; 8: 61 – 5. [PubMed] [CrossRef]
2. Cheek DB, Perry JW. A salt wasting syndrome in infancy. *Arch Dis Child* 1958; 33: 252 – 6. [PubMed] [CrossRef]

3. Giapros VI, Tsatsoulis AA, Drougia EA et al. Rare causes of acute hyperkalemia in the 1st week of life. Three case reports. *Pediatr Nephrol* 2004; 19: 1046 – 9. [PubMed] [CrossRef]
4. Levin TL, Abramson SJ, Burbige KA et al. Salt losing nephropathy simulating congenital adrenal hyperplasia in infants with obstructive uropathy and/or vesicoureteral reflux—value of ultrasonography in diagnosis. *Pediatr Radiol* 1991; 21: 413 – 5. [PubMed] [CrossRef]
5. Speiser PW, Stoner E, New MI. Pseudohypoaldosteronism: a review and report of two new cases. *Adv Exp Med Biol* 1986; 196: 173 – 95. [PubMed] [CrossRef]
6. Sartorato P, Khaldi Y, Lapeyraque AL et al. Inactivating mutations of the mineralocorticoid receptor in Type I pseudohypoaldosteronism. *Mol Cell Endocrinol* 2004; 217: 119 – 25. [PubMed] [CrossRef]
7. Riepe FG, Krone N, Morlot M et al. Autosomal-dominant pseudohypoaldosteronism type 1 in a Turkish family is associated with a novel nonsense mutation in the human mineralocorticoid receptor gene. *J Clin Endocrinol Metab* 2004; 89: 2150 – 2. [PubMed] [CrossRef]
8. Schambelan M, Sebastian A, Rector FC Jr. Mineralocorticoid-resistant renal hyperkalemia without salt wasting (type II pseudohypoaldosteronism): role of increased renal chloride reabsorption. *Kidney Int* 1981; 19: 716 – 27. [PubMed] [CrossRef]
9. Rodríguez-Soriano J, Vallo A, Oliveros R et al. Transient pseudohypoaldosteronism secondary to obstructive uropathy in infancy. *J Pediatr* 1983; 103: 375 – 80. [PubMed] [CrossRef]
10. Klingenberg C, Hagen IJ. Transient pseudohypoaldosteronisme hos spedbarn med vesikoureteral refluks. *Tidsskr Nor Lægeforen* 2006; 126: 315 – 7. [PubMed]
11. Pumberger W, Frigo E, Geissler W. Transient pseudohypoaldosteronism in obstructive renal disease. *Eur J Pediatr Surg* 1998; 8: 174 – 7. [PubMed] [CrossRef]
12. Bühlmann G, Schuster T, Heger A et al. Transient pseudohypoaldosteronism secondary to posterior urethral valves—a case report and review of the literature. *Eur J Pediatr Surg* 2001; 11: 277 – 9. [PubMed] [CrossRef]
13. Maruyama K, Watanabe H, Onigata K. Reversible secondary pseudohypoaldosteronism due to pyelonephritis. *Pediatr Nephrol* 2002; 17: 1069 – 70. [PubMed] [CrossRef]
14. Wang YM. Pseudohypoaldosteronism with pyloric stenosis—a patient report. *J Pediatr Endocrinol Metab* 1997; 10: 429 – 31. [PubMed] [CrossRef]
15. Bashour BN, Balfe JW. Urinary tract anomalies in neonates with spontaneous pneumothorax and/or pneumomediastinum. *Pediatrics* 1977; 59 (suppl): 1048 – 9. [PubMed]
16. Ashkenazi S, Merlob P, Stark H et al. Renal anomalies in neonates with spontaneous pneumothorax – incidence and evaluation. *Int J Pediatr Nephrol* 1983; 4: 25 – 7. [PubMed]
17. Hooper SB, Harding R. Fetal lung liquid: a major determinant of the growth and functional development of the fetal lung. *Clin Exp Pharmacol Physiol* 1995; 22:

235 – 47. [PubMed] [CrossRef]

18. Kizilcan F, Tanyel FC, Cakar N et al. The effect of low amniotic pressure without oligohydramnios on fetal lung development in a rabbit model. *Am J Obstet Gynecol* 1995; 173: 36 – 41. [PubMed] [CrossRef]

19. Watanabe T, Yamazaki A. Pneumothorax and transient pseudohypoaldosteronism in an infant with hydronephrosis. *Pediatr Nephrol* 2003; 18: 62 – 4. [PubMed] [CrossRef]

20. Rodríguez-Soriano J, Vallo A, Quintela MJ et al. Normokalaemic pseudohypoaldosteronism is present in children with acute pyelonephritis. *Acta Paediatr* 1992; 81: 402 – 6. [PubMed] [CrossRef]

21. Nandagopal R, Vaidyanathan P, Kaplowitz P. Transient pseudohypoaldosteronism due to urinary tract infection in infancy: a report of 4 cases. *Int J Pediatr Endocrin* 2009; 2009: 195728.

Publisert: 18. September 2012. Tidsskr Nor Lægeforen. DOI: 10.4045/tidsskr.11.1026

Received 11 November 2011, first revision submitted 22 February 2012, approved 25 May 2012. Medical editor: Siri Lunde.

© Tidsskrift for Den norske legeforening 2026. Downloaded from tidsskriftet.no 3 July 2026.